

Bibliothèque numérique

medic@

**Dictionnaire des maladies
éponymiques et des observations
princeps : Crohn (maladie de)**

**CROHN, Burrill Bernard. - Regional
ileitis. A pathologic and clinical entity**

In : JAMA, 1932, Vol. 99, pp. 1323-29

important in making the intestinal incision for any ureteral transplantation. The intestine should be held by four traction loops, which, when possible, should include any visible vessel in the intestinal wall that may cross the proposed line of incision. With a very sharp lance pointed knife, the peritoneum and part of the muscular coat are cut. The knife is now turned flatwise and with the point of the knife the remaining muscle fibers are teased through with gentle strokes, which cause the muscle ends to separate without damage to the submucosal vessels or membrane. With the handle of the knife, the muscle coat is pushed back, exposing the outer surface of the intestinal mucous membrane. This part of the operation must be done very delicately.

Technic 3, because of its simplicity, seems destined to assume an important rôle. Based on experimental surgery on animals and the very limited experience reported herein, it seems safe to say, even now, that it is the method of choice for treating exstrophy of the bladder in young children and in case of accidental injury to a ureter in the course of an abdominal or a pelvic operation. Conceivably, after it has been more fully tried and developed, it may supplant other methods in all cases whenever two good kidneys are present. It must constantly be borne in mind that *simultaneous bilateral transplantation cannot be done by this technic*. Of three dogs in which bilateral transplantation was done by this technic, all died within forty-eight hours. It is not feasible in dilated ureters with damaged kidneys, in single ureters in which the other kidney has been removed for tuberculosis, or in cases of advanced cancer in which time is important.

Technic 2 has given remarkable results in patients with two good kidneys, such as are usually found in vesicovaginal and other types of fistulas. I have had no deaths in this type of case and under the circumstances would hesitate to use any other method. Nevertheless, it is a serious operation in the hands of those who are not well grounded in the principles and fine points of abdominal and intestinal surgery.

Technic 3 will be a much safer operation in the hands of one who is doing his first transplantation operation. This technic is attractive from another standpoint. It is so simple that it lends itself perfectly to experimental surgery, by which any surgeon preparing to do ureteral transplantation may readily perfect his technic before he attempts to do the operation on the human being. Most of my experimental work was done in my regular operating room. After I had completed the morning's work, an anesthetized dog was brought in and the operation performed, after which the dog was easily cared for outside without any special surroundings. I would not convey the impression that this operation is without danger, for the fate of the kidney depends on the accuracy of a very delicate operation. If the transfixion suture does not definitely penetrate both the lumen of the ureter and the lumen of the intestine, the kidney is lost. Sometimes it is difficult to isolate definitely a ureter from its surrounding connective tissue. The degree of tightness with which the transfixion suture is tied is important. It must be sufficiently tight to strangulate the tissues within its bite but not sufficient to cut through the intestinal mucous membrane at the time it is placed. I would especially urge the use of experimental surgery as preliminary training for the performance of this operation.

611 Lovejoy Street.

REGIONAL ILEITIS

A PATHOLOGIC AND CLINICAL ENTITY

BURRILL B. CROHN, M.D.

LEON GINZBURG, M.D.

AND

GORDON D. OPPENHEIMER, M.D.

NEW YORK

We propose to describe, in its pathologic and clinical details, a disease of the terminal ileum, affecting mainly young adults, characterized by a subacute or chronic necrotizing and cicatrizing inflammation. The ulceration of the mucosa is accompanied by a disproportionate connective tissue reaction of the remaining walls of the involved intestine, a process which frequently leads to stenosis of the lumen of the intestine, associated with the formation of multiple fistulas.

The disease is clinically featured by symptoms that resemble those of ulcerative colitis, namely, fever, diarrhea and emaciation, leading eventually to an obstruction of the small intestine; the constant occurrence of a mass in the right iliac fossa usually requires surgical intervention (resection). The terminal ileum is alone involved. The process begins abruptly at and involves the ileocecal valve in its maximal intensity, tapering off gradually as it ascends the ileum orally for from 8 to 12 inches (20 to 30 cm.). The familiar fistulas lead usually to segments of the colon, forming small tracts communicating with the lumen of the large intestine; occasionally the abdominal wall, anteriorly, is the site of one or more of these fistulous tracts.

The etiology of the process is unknown; it belongs in none of the categories of recognized granulomatous or accepted inflammatory groups. The course is relatively benign, all the patients who survive operation being alive and well.

Such, in essence, is the definition of a disease, the description of which is based on the study, to date, of fourteen cases. These cases have been carefully observed and studied in their clinical course; the pathologic details have resulted from a close inspection of resected specimens from thirteen of fourteen patients operated on by Dr. A. A. Berg.

RELATIONSHIP OF REGIONAL ILEITIS TO OTHER BENIGN INTESTINAL PROCESSES

There exists in the medical literature a heterogeneous group of benign intestinal lesions which have now and then been described under the caption of "benign granulomas." The latter loose term covers a multiplicity of conditions in which both large and small intestines may be involved; it includes all chronic inflammatory lesions of the intestine whose etiology is either unknown or attributable to an unusual physical agent. It represents a hodge-podge or melting-pot in which are thrown all those benign inflammatory intestinal tumors which are neither neoplastic nor due to a specific bacterial agent. Within this group one finds descriptions of foreign body tumors, chronic perforating lesions with gross inflammatory reactions, traumas of the mesentery with intestinal reactions, Hodgkin's granuloma, a late productive reaction to released strangulated hernias of the intestinal wall and numerous other and similar conditions. The so-called benign granulomas all present a tumor-like inflammatory mass which usually simulates carcinoma

From the Mount Sinai Hospital.
Read before the Section on Gastro-Enterology and Proctology at the Eighty-Third Annual Session of the American Medical Association, New Orleans, May 13, 1932.

but which eventually unmasks itself as probably an infectious process of unknown causation. The multiplicity of the possible sites of gastric, intestinal or colonic involvement and the accompanying protean clinical manifestations defeat any effort to include them all in a clear cut clinical entity. The very confusion defies classification.

In this literature, however, there have appeared on occasions references and descriptions that approach the picture that we are about to describe. The entire literature of benign granulomas was reviewed in 1920 by Tietze,¹ who not only described his own cases but covered all previous medical publications. There is nowhere in his encyclopedic article a description which resembles that of regional ileitis. In 1923, Moschcowitz and Wilensky,² in describing four cases of benign intestinal granuloma, detailed one case of a disease involving the terminal ileum which closely resembled that in our cases. They grouped it with various other and similar colonic masses as granuloma. Mock³ in 1931 again described granuloma, but included no example that resembled the cases we have studied.

Just as the generic term of typhus originally included various diseases, from which group eventually typhoid fever, Brill's disease, Rocky Mountain fever, tabardillo and others were split off, so, similarly, do we aim to disintegrate from the general group of varied diseases spoken of as a "benign granuloma" a specific clinical entity with constant and well defined characteristics, which we propose to name "regional ileitis."

PATHOLOGIC ANATOMY OF THE DISEASE

All the specimens obtained by resection were in patients who had been ill for at least a year. We therefore have no specimen exhibiting the very early phases of the disease. The latter are sometimes encountered at the operating table following an illness of from one to two weeks and diagnosed, as a rule, as acute appendicitis. At this time the terminal ileum is found thickened, soggy and edematous; the serosa is a blotchy red. The mesentery of the terminal ileum is greatly thickened and contains numerous hyperplastic glands. Owing to the possibility of spontaneous resolution, resection has never been performed at this stage, so that we have no knowledge of the intra-intestinal changes present at this time.

The inflammatory process is not, however, a static one, nor is the entire diseased segment affected at one time. The oldest lesions begin apparently at, or just oral to, the ileocecal valve, and the more recent ones are situated proximally. In some of our relatively early cases, we have found isolated lesions separated from the main hypertrophic mass by normal mucosa. These isolated areas are, in our opinion, the earlier and primary lesions of the disease; they consist of oval mucosal ulcerations, about 1 cm. in diameter, located on the mesenteric border of the small bowel and lying in the long axis of the intestine, where a sort of groove is naturally formed by the attachment of the mesentery.

The characteristic, fully developed hypertrophic process is, as a rule, limited to the distal 25 to 35 cm. (10 to 14 inches) of the terminal ileum, including the ileal side of Bauhin's valve and terminating rather abruptly at that point. The most advanced pathologic changes are present at the valve, which in some instances becomes converted into a rigid diaphragm with a small irregular opening. Proximally the severity of the

process gradually abates, shading off into normal mucosa. The normal intestinal folds are distorted and broken up by the destructive ulcerative process and rounded and blunted by edema, giving a bullous structure to the mucosal aspect of the intestine, or frequently a cobblestone appearance of the surface of the mucosa may result. A series of small linear ulcerations lying in a groove on the mesenteric side of the bowel is almost always present. Whether these are the remnants of the original ulcerative lesions or whether they are mechanical erosions due to the formation of a *darmstrasse* by the shortening of the fibrotic mesentery, it is impossible to say.

The submucosal and, to a much lesser extent, the muscular layers of the bowel are the seat of marked inflammatory hyperplastic and exudative changes. As a result of these, the wall of the bowel becomes enormously thickened, frequently reaching two or three times its normal density. The lumen of the bowel is greatly encroached on, becomes irregularly distorted and, at times, is only large enough to admit a medium-sized probe. The intestine proximal to the involved segment frequently, but not invariably, becomes greatly dilated and may show superficial irregularly placed tension ulcers. When seen at the operating table, the involved loop is a soggy hose-like mass.

In the older phases of the disease, the exudative reaction is replaced by a fibrostenotic process, and the mucosa appears atrophic with occasional superficial erosions and islands of papillary or polypoid hyperplasia. The serosa loses its gloss and frequently exhibits tubercle-like structures on its surface. The mesentery of the affected segment is greatly thickened and fibrotic, as is the subserosal intestinal fat.

A marked feature is the tendency toward perforation. Free perforation into the peritoneal cavity has not been encountered in this series. The chronic perforation apparently occurs slowly enough to permit of walling off by adhesions to a neighboring viscus, to the parietal peritoneum or to the omentum. There is a marked tendency to the formation of internal fistulas, the sigmoid having been the seat of fistulous involvement four times and the ascending colon and cecum once each. The walled-off abscesses resulting from slow perforation into the peritoneal cavity are, as a rule, considered appendicular in origin. When drained, they give rise to chronic intractable fecal fistulas which defy attempts at simple closure because of the persistence of the underlying inflammatory disease in the bowel. Indirect perforation of the cecum may result from perforation of the ileum into the terminal mesentery with secondary cecal termination of the fistulous tract. Pericecal fibrotic and inflammatory changes which result from the proximity of the ileal focus to the cecum are probably responsible for the roentgenologic changes in the contour of the ascending colon and cecum, such as may be easily confounded with the defect of hyperplastic tuberculosis.

Microscopically, no specific features can be demonstrated. The stained histologic sections showed various degrees of acute, subacute and chronic inflammation, with variations in the predominance of polymorphonuclear, round cell, plasma cell and fibroblastic elements. In the early stages the lesion is a diffuse one, involving mainly the mucosa and submucosa, with the presence of some inflammatory serosal reaction. The mucous membrane shows areas of marked destruction, and at times the glandular structure is almost completely gone, leaving an atrophic layer of epithelium, the result of a regenerative process. In later stages of the disease, the

1. Tietze: *Ergebn. d. Chir. u. Orthop.* 12: 212, 1920.

2. Moschcowitz, E., and Wilensky, A.: *Am. J. M. Sc.* 166: 48, 1923; 173: 374, 1927.

3. Mock, H. E.: *Surg., Gynec. & Obst.* 52: 672, 1931.

inflammatory reaction is more focal in character. These focal areas of inflammation in the serosa give the appearance, on gross examination, of tubercles.

In some of the cases, the presence of giant cells is quite striking. Special stains have occasionally demonstrated the presence of large pale cells, or groups of cells, probably vegetable in nature, in the vicinity of the giant cells. They could be demonstrated frequently in all the layers of the intestine. These and the giant cells are probably not an essential feature of the pathologic changes in this condition. They are, more likely, accidental findings due to the inclusion of small particles of vegetable matter which have become entrapped in the ulcers, entered the lymphatics and become encapsulated in the process of healing. The resultant foreign body reaction around these nonabsorbable particles results in the presence of the giant cells. To some extent they may be contributory to the marked hypertrophic scarring which occurs. We believe that the attempts, by some authors, to classify this granulomatous condition as an unusual form of tuberculosis were, to a great extent, predicated on the assumption that the giant cells were, necessarily, evidences of tuberculosis.

It is quite likely that in the past this granulomatous condition was confounded with ileocecal tuberculosis, and so missed as a clinical and pathologic entity. The failure of the pathologic reports in our cases to substantiate a suspicion of tuberculosis led us to exercise still greater caution in eliminating a Koch infection as the etiologic agent. With the assistance of Dr. Paul Klemperer in determining moot points, sections from the various cases were again reviewed. No evidences of tuberculosis, syphilis, actinomycosis, Hodgkin's disease or lymphosarcoma were found. Guinea-pig, rabbit and chicken inoculations of triturated material from mesenteric glands and from the intestinal wall proved negative for tuberculosis in five cases. Löwenstein tubercle cultures were also negative in three instances. It is interesting to note that none of these clinical cases presented any evidence of pulmonary tuberculosis; there were no positive Wassermann reactions in this series.

The relation of appendicitis and previous operations to the development of the disease is of some interest. Half of the patients had been subjected to appendectomy before the final resection was performed. In about half of those cases, abnormalities of the terminal ileum were already noted at the time of that operation. In those cases in which there had been no previous appendectomy, the mucosa of the appendix was not involved, as might be expected from the fact that the disease stops on the ileal side of the valve. Inflammation of the outer coats of the appendix, due to the presence of adjacent inflammatory disease, was common.

THE CLINICAL FEATURES

Etiologically, young adults comprise the largest number of patients. Only two of the patients studied were over 40 years, the average incidence being at 32 years of age; the youngest patient was 17, the oldest 52. Males predominate over females in the proportion of nearly 2:1. There are no known predisposing factors.

Cases of regional ileitis run, in general, a fairly constant and typical clinical course. Most of the patients had been ill for from several months to two years before coming under observation. During this time the outstanding complaints were fever, diarrhea, continuous loss of weight and a progressive anemia. The clinical picture resembles that of a nonspecific ulcerative colitis.

Fever is rarely high, long periods of apyrexia being interspersed with shorter and irregular cycles of moder-

ate temperature. Occasionally, though rarely, the temperature rises above 103 F. Some of the cases run the complete course without fever.

Diarrhea is usually an outstanding feature, though the number of movements and the intensity of the actions never approach those of a true colitis. The average patient has from two to four loose or semisolid daily defecations, sometimes with blood and always with mucus. The stools are rarely mushy or liquid and contain free pus, coagulated lumps of mucus and streaks of blood, but tenesmus is always lacking. There are none of the perianal fistulas, condylomas or perirectal abscesses that characterize the complications of true colitis, for in this disease the rectum and colon are never involved. At times, particularly when the stenotic factor predominates, as in the later periods of the course, constipation rather than diarrhea predominates.

Vomiting characterizes the stenotic type of cases, is never marked or persistent and is usually accompanied by abdominal pain and visible peristalsis.

Pain distributed over the lower abdominal parietes is a common feature of the disease. This pain is dull and cramplike and accompanies, or is followed and relieved by, defecation. It is usually localized to the right lower quadrant and is occasionally referred across the abdomen to the whole lower abdominal region. Occasionally, and not infrequently, when the sigmoid, as is not unusual, becomes adherent to the necrotizing hyperplastic ileum, fistula formation occurs between these two hollow viscera. In these cases the pain is mainly localized over the left lower abdominal quadrants; the mass which is then felt abdominally and per rectum may appear to be an integral disease of the rectosigmoid area.

The general symptoms are those of weakness, usually a rapid and progressive loss of weight, and an anemia which ordinarily is moderate, but which may progress to a severe degree. In the milder cases, however, there may be little or no emaciation and no anemia. The stools contain constantly occult blood. Appetite is poor, particularly during the febrile bouts.

A moderate leukocytosis characterizes some of the cases; in most, the white blood count is normal. Even in the stenotic cases the blood plasma findings that accompany marked obstructions of the upper alimentary tract are rarely seen.

PHYSICAL EXAMINATION

Certain physical findings characterize this disease, the most constant ones being (1) a mass in the right iliac region, (2) evidences of fistula formation, (3) emaciation and anemia, (4) the scar of a previous appendectomy and (5) evidences of intestinal obstruction.

1. A moderate-sized mass is usually felt in the lower right iliac region or in the lower midabdomen. The mass is usually the size of a small orange, tender, firm, irregular and only slightly movable. This mass is composed of the tremendously hyperplastic ileum, the stenotic inflamed ileocecal junction, which may and often does assume a size of from two to five times that of a normal valve of Bauhin, and frequently an adherent section of the colon or sigmoid to which a fistulous tract has been created. When the sigmoid is adherent and involved, the mass may lie more to the left; when the cecum or ascending colon or hepatic flexure constitutes the distal end of the fistulous tract, the mass may lie more to the right and higher in the abdomen. When the fistulous tract burrows into and through the mesentery, the necrotic process may cause a diffuse mesenteric suppuration which participates in the formation of the mass. The tumor is usually palpable per rectum, though felt only very high with the examining finger.

2. Fistula formation is a constant feature of the disease process. The most common site of adherence is the sigmoid; next in frequency is the cecum and the ascending colon and occasionally the hepatic flexure. As the necrotizing process of the mucosa of the ileum progresses through its several coats, the serosa becomes involved. Any hollow viscus, usually the colon, now becomes adherent to the point of threatened perforation. A slowly progressive perforation is thus walled off, but results in a fistulous tract being formed between the two viscera. In one case the uterus formed the limiting organ of a threatened perforation. In another case, on sigmoidoscopic examination, a nipple-like papillomatous projection was seen high in the rectum, or just above the rectosigmoid angle. This observation was noted at the time, but the proper interpretation was overlooked; it was the colonic end of a perforating fistulous tract. In still another case, the anterior abdominal wall presented a fecal fistula, particularly such as persists after a fruitless appendectomy. These fistulas are usually regarded as cecal in point of origin; they are always, however, communications between the necrotic ileum and the anterior abdominal wall.

3. There are evidences of emaciation and anemia.

4. In at least half of the cases the appendix had been removed at some previous operation. This appendectomy usually antedated by several months or years the present symptoms. In many cases the appendix had been removed several months previous, at which time thickening and tumor-like massive inflammation of the small intestine and mesentery had been noted, though nothing beyond the appendectomy had been attempted. It seemed quite evident that in these cases the lower right abdominal symptoms had resulted in the discovery or in the overlooking of the real pathologic process in the terminal ileum. In all such cases the pathologic report cited "acute and chronic inflammatory changes of the appendix," a report which really whitewashed this organ as a participant in the disease process. In fact, we now know that the process never transcends the limit of Bauhin's valve, and that the appendix is always free from guilt and free from changes.

5. In those cases in which the process has progressed to a stenotic stage, the physical findings are those of intestinal obstruction. Loops of distended intestine may be visible through the emaciated abdominal wall, and puddling is frequently observed in the flat x-ray plates. Visible peristalsis is not uncommon and is accompanied by borborygmus and the passage of gas with evident relief. The visible loops of the distended intestine are usually localized to the lower midabdomen. General distention and ballooning of the whole abdomen are unusual.

CLINICAL COURSE OF THE DISEASE

There are four various types of clinical course under which most of the cases may be grouped: (1) acute intra-abdominal disease with peritoneal irritation, (2) symptoms of ulcerative enteritis, (3) symptoms of chronic obstruction of the small intestine and (4) persistent and intractable fistulas in the right lower quadrant following previous drainage for ulcer or abdominal abscess.

1. *Signs of Acute Intra-Abdominal Inflammation.*—It is impossible to distinguish these cases preoperatively from those of acute appendicitis. There are generalized colic, pain and tenderness in the right lower quadrant and fever up to 101 or 102 F. The white blood count is elevated. The development of symptoms seems to be somewhat slower than in appendicitis. The presence

of a mass even without actual abscess formation is a fairly constant feature. The picture encountered at operation is that of a greatly thickened, red or blotchy terminal ileum, with marked edema of the surrounding tissues and slight exudate of the ileal wall. The mesentery is thickened and edematous, and contains numerous large glands. There is usually clear fluid present in the abdomen. The appendix may appear, and shows evidence of a periappendicitis without mucosal involvement. In some cases an abscess is encountered; in our experience the pus has been thick and grumous, and not as foul smelling as an abscess of appendiceal origin. The future course of these cases cannot be predicted. Some seem to undergo resolution, others to pass into one of the more chronic phases of the disease. Those cases which are drained may develop intractable fistulas.

2. *Symptoms of Ulcerative Enteritis.*—These patients complain of colicky periumbilical or lower abdominal pain. There is a tendency toward looseness of the bowels (from three to five movements a day). The stool is usually liquid or mushy and contains pus, mucus and occult or visible blood. There is no gross melena. A constant fever is present, but the temperature is rarely above 100 F. With the progress of the disease, a marked secondary anemia may develop, reaching as low as 35 per cent hemoglobin. Considerable loss of weight and strength may occur. In some instances disturbances of general nutrition are slight. This course may continue for as long as a year until exhaustion sets in, or more commonly the cases pass gradually into the stenotic phase of the disease.

3. *Stenotic Phase.*—This is the type most commonly encountered. The symptoms in this stage are those of a subacute or small intestinal obstruction of varying severity. The obstruction, as in most obliterating lesions of the small bowel, is not complete. Violent cramps, borborygmus, occasional attacks of vomiting and constipation are present. Visible peristalsis and intestinal erection are common. A palpable mass is practically always present in the lower right quadrant. In this phase of the disease fistulous communications with the colon or sigmoid may lead to the signs and symptoms of colitis, and mask the true nature of the disease. Occasionally the stenotic phase occurs as a primary manifestation of the disease; again, the symptoms may have been present for years (four years in one of our cases).

4. *Persistent Fistulas.*—Even before we had had a resected specimen to confirm our suspicion, we felt that a certain number of the persistent and intractable intestinal fistulas which followed on the drainage of a supposedly appendiceal abscess were in reality due to a nonspecific inflammatory disease involving the terminal ileum. This belief was founded on the following observations: 1. In a number of instances at the time of the second or third operation for closure of the fistulas, the appendix was found intact and not diseased. 2. Removal of the specimens from the sinus tract and from the intestinal end of the fistula failed to reveal any evidence of tuberculosis or other specific disease. 3. The occurrence of ileal without cecal origin of the sinus tract was noted. 4. The tendency of fecal fistulas of simple appendiceal origin is to close spontaneously or to be susceptible of closure by excision of the tract and inversion of the stump. However, in two instances resection of the intestine and fistulous tract revealed the typical pathologic picture of ileitis. We assume, therefore, that fistulas which are of supposedly appendiceal origin, but which have ileal openings and which have resisted simple surgical closure are, in the absence of

tuberculosis, to be considered as cases of regional ileitis. One peculiar feature of these fistulas may be remarked: They may develop a few months after the original drainage operation, the wound meanwhile having healed and having remained healed for a few months. An abscess then develops in the wound; when this abscess mass is investigated, a communication with the intestine may be demonstrated.

ROENTGENOGRAPHIC OBSERVATIONS

Two outstanding facts, one negative and the other positive, are regularly noted. Since the disease simulates regularly the clinical characteristics of ulcerative colitis, the barium enema is first attempted. This procedure results in a negative report. The reason for this is evident in the light of the pathology of the disease. The colon is uniformly free from changes, even though the ileocecal valve is the seat of greatest intensity of the process.

The barium meal, however, when carefully interpreted, gives definite positive findings. These usually consist of distended loops of terminal ileum, in which a fluid level is discernible, and a definite delay in motility of the meal through the distal end of the small intestine. In the four, six and nine hour observations this delayed motility is usually present, though only in the late or stenotic stages is the delay striking. The milder degrees of stasis and puddling in the ileal loops may easily be overlooked by any but a careful roentgenologist. Even when the condition is plainly indicated, the true significance of these reported results may be glossed over by the clinician and an exact diagnosis may thus be missed.

When the ascending colon is the seat of a fistulous communication with the ileum, one may note some stricture deformity of the ascending colon or hepatic flexure, with delayed motility at this point. When the sigmoid is similarly involved in a fistulous tract, a true narrowing and delay at this flexure may simulate carcinoma and so create the necessary indication for operation. Both these areas of stenotic deformity of the large bowel are incidental to only one of the complications of the disease, namely, the formation of fistulous tracts. The entire colon is otherwise exonerated as a primary site of the granulomatous inflammation.

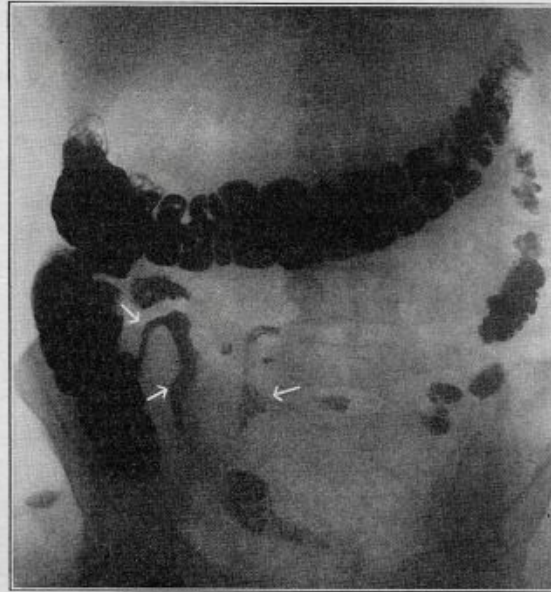
DIFFERENTIAL DIAGNOSIS

Regional ileitis must be differentiated from several analogous conditions which produce a mass in the right iliac region with diarrhea and fever. The most important differentiation is that of regional ileitis from nonspecific ulcerative colitis. The sigmoidoscopy and the barium enema suffice for the recognition of colitis in the largest percentage of cases. But there are types of colitis which involve only the proximal segments of the

colon, and in which the sigmoid and the rectum are free from pathologic changes. While these instances are few and relatively uncommon, they do occur and lead to much confusion; they may be recognized by the deformity and spasm of the cecum and ascending colon when the latter areas are the seat of the segmental phenomena of colitis. Only in severe cases of ulcerative colitis does the process involve the terminal ileum, and then only for a few inches. In regional ileitis, all of the damaged tissue is proximal to the valve. The diagnosis is purely roentgenographic, the clinical differentiation being impossible. Colitis does not cause fistulas except about the anus and rectum; a mass is rarely palpable in colitis.

Ileocecal tuberculosis as a primary process should be easy of differentiation from regional ileitis. We are inclined, however, to agree with Moschowitz and Wilensky² in the skepticism with which they view the

actual occurrence of a primary tuberculous process at the ileocecal junction. To repeat their arguments, the latter disease must be rare, for only three cases have been seen at Mount Sinai Hospital in several years. Pathologic examination of all such suspected tuberculous masses has uniformly failed in the demonstration of tubercles or of tubercle bacilli in the sections or smears. Practically all cases mistakenly suspected of, or diagnosed as, ileocecal tuberculosis have been eventually classed as new growth, as appendicitis with abscess or as benign nonspecific granuloma. In all of our first cases of regional ileitis the diagnosis of ileocecal tuberculosis was the unvarying best possibility; operation was undertaken only after the customarily



Roentgenogram of the barium meal given by mouth, showing regional ileitis. Note the extent of the strictured area.

accepted methods of treatment for tuberculosis had been exhausted.

Fibroplastic appendicitis or typhlitis is a disease better known to the surgeons.

Lymphosarcoma, intestinal or mesenteric tuberculosis and Hodgkin's disease simulate regional ileitis in many of its features. The exact differentiation is possible only at the operating table or by the examination of pathologic specimens. Sarcoma of the intestine is usually multiple, causing dilatations at various levels, and involves the jejunum as well as the ileum and not particularly just the terminal 8 to 12 inches of the small intestine. Hodgkin's disease may give its characteristic monocytic blood picture, or a regional lymph node may reveal the true nature of the process.

Actinomycosis of the ileocecal region with fistula formation to the external abdominal wall must always be mentioned in the differentiation from ileitis. The extreme rarity of actinomycosis in this region of the body and in this climate makes this differentiation more theoretical than necessary.

From carcinoma of the terminal ileum or of the ileocecal valve the differentiation cannot be made with any certainty; both conditions call for surgical intervention, and both lead to cure by successful and early resections.

TREATMENT

Medical treatment is purely palliative and supportive. The diseased area cannot be reached by colonic irrigations or enemas, and any attempts by medical means to reach a necrotizing, ulcerating and stenosing inflammation of the terminal ileum is purely and essentially futile. True, one case, discovered in the course of a cholecystectomy for stones, progressed to spontaneous healing or at least to a cessation of the intestinal symptoms.

But in general, the proper approach to a complete cure is by surgical resection of the diseased segment of the small intestine and of the ileocecal valve with its contiguous cecum. The restitution to complete health in thirteen out of fourteen cases as a result of the radical resection of the pathologic process or of a short-circuiting operation speaks vehemently in favor of surgical methods as the logical successful therapeutic procedure.

In one instance recurrent symptoms were accounted for by the finding of an annular stenosis a short distance proximal to the new anastomosis (ileotransversostomy). Apparently in this case the resection had not been carried out sufficiently oral to the lesion completely to eradicate the disease.

Our experience with short-circuiting anastomoses is limited. In one case a short-circuit ileocolostomy was performed through a segment of ileum that was apparently normal at the time of operation. The pathologic process did not heal; on the contrary, the disease progressed to the proximal loop of the anastomosis. In two cases of intractable fistulas and in one case of inflammatory pelvic mass, ileocolostomy with exclusion has given excellent results. The best operation, as devised by Dr. A. A. Berg, consists of dividing the ileum 3 feet (91 cm.) from the ileocecal junction, closing both ends of the divided ileum and implanting the proximal terminus of the ileum by a side-to-side anastomosis at the transverse colon.

ABSTRACT OF DISCUSSION

DR. J. A. BARGEN, Rochester, Minn.: This presentation would seem timely, for, with improved roentgen technic and more intensive study of intestinal disease, the condition may prove to be less common than it is now supposed to be. Intensive roentgenologic investigation often becomes necessary to determine the nature of disturbances of the ileocecal coil. Undoubtedly some of these cases have been overlooked. In the last few years, several cases annually of this type have come to operation at the Mayo Clinic. Usually the appendix has been removed for complaints similar to those for which the patients presented themselves, that is, recurrent and intermittent attacks of right abdominal pain and discomfort. Some of these conditions were diagnosed preoperatively because of the suggestive roentgenographic and roentgenoscopic signs. The lumen of the intestine in this region is narrowed, and the wall is thickened and shortened. The gross appearance of the removed specimen resembles closely that of the colon in advanced chronic ulcerative colitis. The lesion is inflammatory, containing fibrotic elements and granulation tissue as well as evidence of more acute changes. The evidence points to a regional inflammatory disease perhaps on the basis of localized decrease in resistance to some bacterial invasion. I am wondering whether the designation "terminal" is adequately descriptive. To some it has conveyed the meaning of agonal. Perhaps the modifying adjective "regional" or some other word suggesting its localized nature, instead of the end, would be more suitable.

I should like to emphasize that this presentation is an important one, that possibly these cases will be discovered earlier and more frequently in the future, and if so, one instead of two operations may be performed, and that I believe the lesion is infectious.

DR. JULIUS FRIEDENWALD, Baltimore: I am reminded of two cases quite a number of years back in which this condition was evidently present but which were regarded at the time as instances of carcinoma. Both patients, men, presented almost identical symptoms; the one was 50 and the other 58 years of age. The condition arose in the midst of good health and was associated with rapid loss of flesh, diarrhea, indigestion, slight fever and anemia; it terminated in progressive constipation and in attacks of partial and almost complete obstruction. In both instances an indefinite mass could be detected in the cecal region. At operation an extensive obstructive mass was detected in the terminal ileum. A diagnosis of inoperable carcinoma was made by the surgeon and a lateral anastomosis performed. The patients made a surprisingly rapid recovery and remained well. The recovery could not be explained at the time, but the condition was evidently ileitis, as described by the authors. Since then I have observed a number of instances of a milder type which at operation presented a somewhat similar appearance. In a woman, aged 62, who was operated on about two years ago and who presented symptoms of lower right-sided abdominal pain with loss of flesh and attacks of alternating diarrhea followed by intense constipation, this condition was observed in the terminal ileum in a mild form. The surgeon, not realizing its significance, simply removed a chronically inflamed appendix. Since then the attacks have continued, the distress becoming more marked. The authors have undoubtedly described a clinical entity of great importance, a condition that may occur in so severe a form as to simulate carcinoma or intestinal tuberculosis or, in a milder form, presenting the appearance rather of a chronic appendicitis. The possibility of its occurrence must constantly be borne in mind in the differential diagnosis of chronic abdominal disease.

DR. LOUIS J. HIRSCHMAN, Detroit: I have just such a case under my observation, which presents an interesting phase which has not come under the observation of the authors, at least but rarely, as I recall their paper. This is a youth, aged 18 years, who has been suffering from chronic ulcerative colitis since 9 years of age, half his life. His weight has gone down in the last few months to 78 pounds (35.4 Kg.), so much so that when he was sent to me for surgical relief for his chronic ulcerative colitis, having hemorrhages, I decided on intestinal rest, and enterostomy was performed. A diagnosis of benign papilloma of the ileum was not made. He was sent for relief from the chronic ulcerative colitis. At operation, about 12 inches (30 cm.) of a large, doughy, thickened ileum was discovered. It was resected and ileostomy done, with immediate relief. The appendix also was involved. It was done about eight weeks ago and the patient has gained weight so that he weighs now about 130 pounds (59 Kg.). The interesting point to me is that when the specimen was opened the ileum was almost occluded with granulomas. It was a wonder he had any peristalsis or intestinal movement. I gathered from what the authors said that it is uncommon to have an ulcerative colitis in connection with a granulomatous infection of the terminal ileum. In this case there was no evidence of fistulas in connection with either the terminal ileum or the large intestine and I wondered why, since there is the granulomatous formation they described.

DR. SIDNEY A. PORTIS, Chicago: What were the bacteriologic observations on the excised portion of the ileum? Did you make any sections of the ileum to find out whether any bacteria were deeply seated in the walls of the ileum?

DR. BURRILL B. CROHN, New York: In a disease of this type, in which an attempt is being made to establish the etiology of the disease, we have naturally taken great pains to exclude every known etiologic factor. Histologic sections were made of the tissues and stained with various types of stains. Cultures were made. Ground material was injected into guinea-pigs and fowl. Various types of laboratory animals were used to eliminate any possible form of tuberculosis. Löwenstein cultures were made. Dr. Klemperer, the pathologist, exhausted

all the known possible scientific methods of finding an etiologic factor. I can say that no etiologic factor was found. It is refreshing to address a medical organization of this kind, where one can count on meeting men of large clinical experience and find that Drs. Bargaen, Friedeuwald and Hirschman have seen cases of this type. I have not had many occasions, in fact this is the first, to read this article. I have spoken extemporaneously at one or two previous meetings and wherever I spoke of this subject, the older clinicians, men with broad experience, surgical or medical, always have said: "We have seen such a thing in past years. We have met with it in surgical experience and didn't know what to do with it." The chairman of the New York Surgical Society, at the time the subject was brought up, said: "I have to operate in such a case and I don't know what to do. I don't know the nature of it." I forgot to mention an important physical sign; namely, the mass that occurs. In these cases a mass develops in the lower abdomen, usually in the right ileac region, consisting of agglutinated coils of ileum massed together. Sometimes the mass will move over from adhesions to the sigmoid and will present more in the left lower abdomen. The mass can usually be felt by rectum. It is a hard mass and a movable mass. It does not feel carcinomatous, though I must say some of the best cases we met had previously been condemned as inoperable carcinomas. In addition to the agglutinated loops of ileum, an inflammatory reaction is set up by the fistulas that travel through the mesentery of the ileum to the loops of the colon. I am thankful for the discussion. I had come to the conclusion that only the abdominal surgeons knew about the condition. I am glad to find that men with older and larger medical experiences have also met with the manifestations of the disease.

DR. FRANK SMITHIES, Chicago: You never found free fluid, did you?

DR. CROHN: Yes, a small amount, not demonstrable by physical signs but a small amount such as one would find in any inflammatory peritoneal lesion—real ascites.

PHYSOSTIGMINE, A PERISTALTIC STIMULANT

P. F. BUTLER, M.D.

AND

MAX RITVO, M.D.

BOSTON

About five years ago, at the suggestion of Dr. Soma Weiss, we began using physostigmine to increase gastric tonus and stimulate peristaltic activity.¹ We found this drug to be of great value in the roentgen examination of the gastro-intestinal tract, and have used it with satisfactory results since that time. Our series now numbers over 1,200 patients and we deemed it of interest to report a summary of our observations in these cases.

Roentgenologists are familiar with the type of patient in whom the roentgen study of the stomach is made difficult if not impossible by the presence of a marked degree of atonicity, absent or sluggish peristalsis or spasm. In these instances, even after prolonged periods of fluoroscopic observation, it is often impossible to obtain satisfactory visualization of all portions of the stomach; or defects may be present without its being possible to determine whether they are due to organic lesions of the stomach, extrinsic pressure or spasm. Spastic deformities in particular may persist for long

Read before the Section on Radiology at the Eighty-Third Annual Session of the American Medical Association, New Orleans, May 12, 1932.

Because of lack of space this article is abbreviated in THE JOURNAL by the omission of some of the illustrations. The complete article appears in the author's reprints.

1. Ritvo, Max, and Weiss, Soma: Physostigmine as an Aid in Gastro-Intestinal Roentgen-Ray Diagnosis, *Am. J. Roentgenol.* **18**: 301 (Oct.) 1927.

periods and be confusing. In the past, various maneuvers have been resorted to in the endeavor to overcome these difficulties. Deep breathing, reassurance and periods of rest during the fluoroscopic observations may be successful in a small proportion of cases. Pressure over the abdomen with the gloved hand or special instruments may be helpful; such manipulation often causes pain or discomfort, however, thereby defeating its own purpose and making the examination still more difficult and unsatisfactory. Atropine has been used in many clinics for years. Most observers agree that atropine even in large doses does not relax spasm of the stomach or pylorus, and this drug is falling into disuse. Amyl nitrite is useful in relaxing spasm of the colon, but is not effective in gastrospasm. These methods are time-consuming, not availing in most instances and may be attended by unpleasant side-effects. This problem has remained a vexing and difficult one, and roentgenologists have long desired its solution.

With physostigmine, it is possible to increase gastric tonus and stimulate peristaltic activity. With the aid of this drug, the routine roentgen examination of the stomach can be completed in a much shorter time than otherwise in the difficult cases with atonicity, absent or sluggish peristalsis or spasm. This lessens the fatigue and exposure to radiation of both the patient and the physician. We also feel that physostigmine has enabled us to attain a much greater accuracy of diagnosis in difficult or doubtful cases than would otherwise have been possible.

The first effect observed after the administration of physostigmine is an increase in tonus. This change occurs within from three to ten minutes and is present in every patient to whom this drug is given. The stomach contracts and becomes much smaller than previously. The outline is distinct and clear, the margins of the stomach shadow being thrown into sharp relief. This is of particular importance in the examination of patients in whom the stomach is dilated, with hazy, indistinct borders. The increased tonicity lasts from about twenty minutes to one hour. After the effect of the drug disappears, the stomach returns to its previous condition and does not appear to be left in a tired-out state.

The increase in peristalsis usually begins within from five to fifteen minutes after the administration of the drug and lasts from a few minutes to half an hour. The waves are deep and powerful as a rule. From two to six waves may be present simultaneously. The opaque meal is forced into every portion of the stomach and through the pylorus, so that both the gastric and the duodenal outlines are visualized with distinctness and clarity. If there is an indurated lesion or organic filling defect in the stomach wall, the peristaltic waves are arrested or broken up at the site of the lesion. If the defect is due to spasm or pressure, the waves are observed to pass directly through the area in question. With pylorospasm particularly it frequently requires the expenditure of much time and effort to visualize the pyloric sphincter and duodenum, and in some instances it is impossible to observe these structures satisfactorily even with long periods of observation. After the administration of physostigmine, the increased peristalsis forces the barium mixture through the pylorus, enabling the roentgenologist to complete the examination in a much shorter time and with a much greater degree of accuracy.