

**Dictionnaire des maladies
éponymiques et des observations
princeps : Zinsser - Engman - Cole
(syndrome de)**

**COLE, H. N. / RAUSCHKOLB, J. E. /
TOOMEY, J. - Dyskeratosis congenita
with pigmentation, dystrophia unguis
and leukokeratosis oris**

*In : Archives of dermatology and syphilology, 1930,
Vol. 21, pp. 71-95*

DYSKERATOSIS CONGENITA WITH PIGMENTATION,
DYSTROPHIA UNGUIS AND LEUKOKERA-
TOSIS ORIS *

H. N. COLE, M.D.

J. E. RAUSCHKOLB, M.D.

AND

JOHN TOOMEY, M.D.

CLEVELAND

At the annual meeting of the Cleveland Dermatological Society held in October, 1926, a case was presented for diagnosis in which the patient showed a peculiar scarflike, pigmented eruption of the neck, an acrocyanosis of the hands and feet with hyperhidrosis of the palms and soles, a dystrophy of the nails and a leukoplakia-like eruption of the tongue and hard palate. The history and description are given subsequently.

REPORT OF CASES

History.—The father, mother and three sisters were living and well. No one in the family had had the same condition as the patient, and he knew of no other relatives who had this trouble.

The patient, a man, aged 20, had had the ordinary diseases of childhood—measles, mumps and varicella. He had been troubled as far back as he could remember with what had been called undernourishment or malnutrition. He was in a severe automobile accident at the age of 13, which resulted in the shortening of one of his legs about an inch. He graduated from high school at the age of 18 and at the time of presentation was attending an art school.

The patient said that as far back as he could remember he had had a peculiar condition of his finger-nails and toe-nails, and a peculiar pigmentation over his neck. He never knew that the skin over his tongue was different from that of other people. He said that his feet perspired freely, that he also noticed a great deal of perspiration on his hands, and that his hair was rather dry. He occasionally had large blisters on the heels, which would sometimes be the size of a castor bean or even that of a half dollar. These bullae, the patient said, were difficult to break, and often a long time would elapse before they broke open.

Examination.—The pupils were equal and round and reacted well to light and accommodation. There was nothing abnormal showing either in the pupillary area or in the cornea. Numerous scars of old chickenpox were noted over the face.

Mucous Membrane: The entire dorsum of the anterior two thirds of the tongue showed a peculiar glazed, whitish appearance. The surface was rather

* Submitted for publication, March 28, 1929.

* Read at the Fifty-Second Annual Meeting of the American Dermatological Association, San Francisco and Del Monte, Calif., July, 1929.

* From the Departments of Dermatology and Syphilology and of Pediatrics of the School of Medicine, Western Reserve University and of the Cleveland City Hospital.

smooth. The natural rugosities of the tongue did not show up so well. The surface was likewise rather shiny, and here and there, distributed over the area, one noted small, bright red spots where there was a break in the leukoplakia-like formation. This was not noted on the inside of the cheeks, but over the hard palate, in about the middle half, there was an area the size of a fifty cent piece, showing this glazed, rather whitish appearance. On the left side of this area there was one spot, the size of a pea, which was slightly raised and of a dense whitish color.

Skin: Over an area extending upward almost to the jaws, backward to just posterior to the ear, and downward in a straight line almost to the clavicles on each side and then converging from each side symmetrically to a point on the sternum about midway between the mammae, one found an eruption most profuse over the anterior portion of the neck, down to the level of the clavicle, but nevertheless involving all the areas described. It was of a peculiar, light, reddish-brown, or possibly grayish-red, tint. It was made of fine, pinhead-sized, smooth, somewhat whitish, raised papules, in linear rows, following the somites of the skin, and with a fine reddish base between these rows. These papules in their

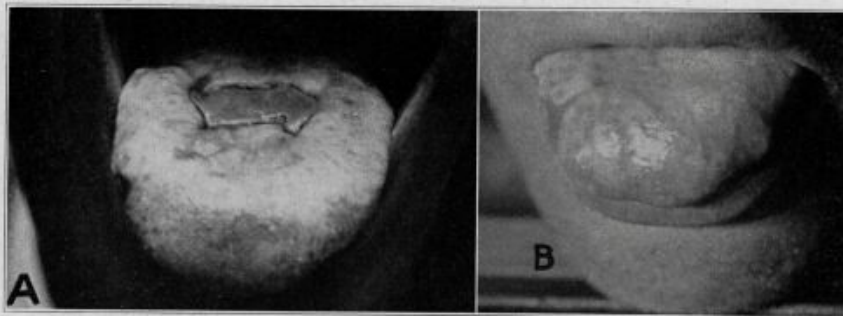


Fig. 1.—*A*, the condition of the tongue, Sept. 1, 1925, with a central open break in the surface which later healed over; *B*, present condition of the tongue with leukoplakia over the anterior end, especially.

linear arrangement were usually closely packed, side by side. Nevertheless, they had a fine, reddish demarcation from the next papules. In some places the reddish color between the rows of papules took on a somewhat grayish-red tint. As one observed the outer border of the areas described, the papules were not so evident. They were separated more widely from one another, and the area gradually fused into the normal skin. The demarcation from the normal skin was most marked above the clavicles on the sides, while down over the sternum it was more difficult to distinguish the involved area from the normal skin. Along the under surface of the upper arm, extending from the axillary space almost to the elbow, there were scattered discrete, brownish macules the size of a pinhead or smaller. There was no evidence, however, of any papular formation. Over each elbow the skin was slightly reddened. The skin was wrinkled somewhat, and a few keratotic papules were noted. Over the knees there was not so much of this wrinkling; there were numerous slightly reddened, raised papules which were follicular in type, some of them showing a fine, dark point in their centers. Both the palms and the soles showed a hyperhidrosis. There was a sug-

gestion of thickening of the skin over the palms. They were reddish, and there was a tendency to cracking of some of the folds of the digits. There was no thickening of the soles. The hands, up to the wrists, showed a reddish color, resembling an acrodermatitis chronica atrophicans. The skin over the dorsa of the digits had a suggestion of thinning and atrophy, and there was a definite anetoderma over the dorsum of the last joint of each finger. Fine parallel venules were scattered over the entire anterior surface of the pinna of the ears.

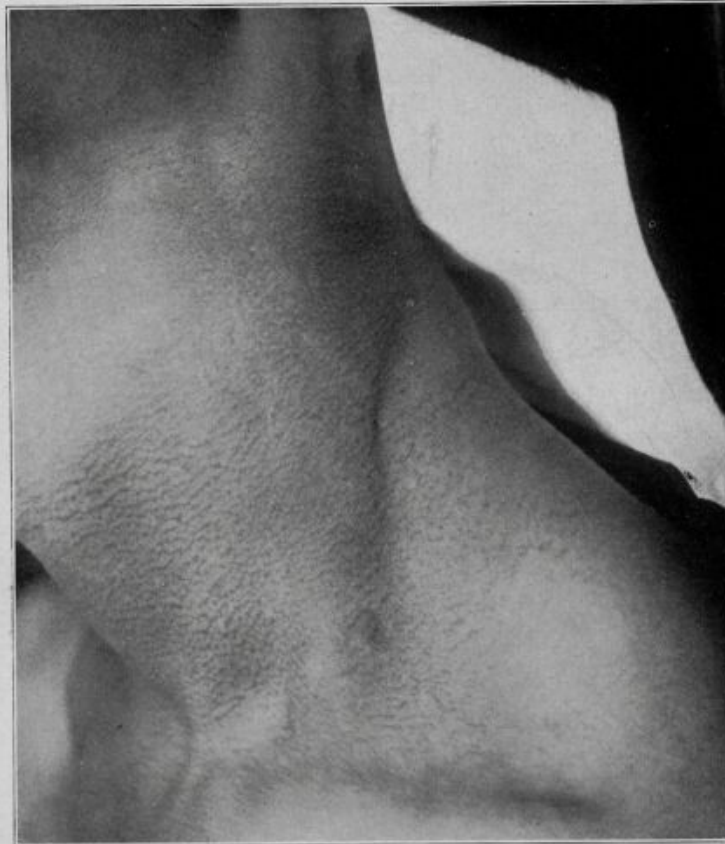

Fig. 2.—Left side of the neck, showing the arrangement of the papules with the reddish-brown pigment in between. Papules are arranged in rows following the somites.

On the heel of the right foot there was a bullous lesion which was broken. It was about 1 cm. wide and about 3 cm. long. No milia were noted in any areas.

Nails of the Hands: All the nails of the fingers and thumbs showed a condition which was almost similar. The base of the nail gradually fused into the skin with little or no sharp demarcation. The nails were smaller than normal, though the nail on the little finger of the right hand was somewhat thickened.

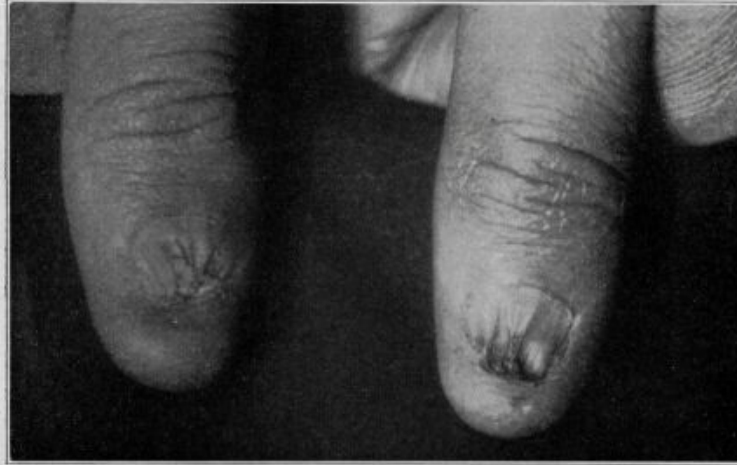

Fig. 3.—Dystrophic condition of the thumb nails.

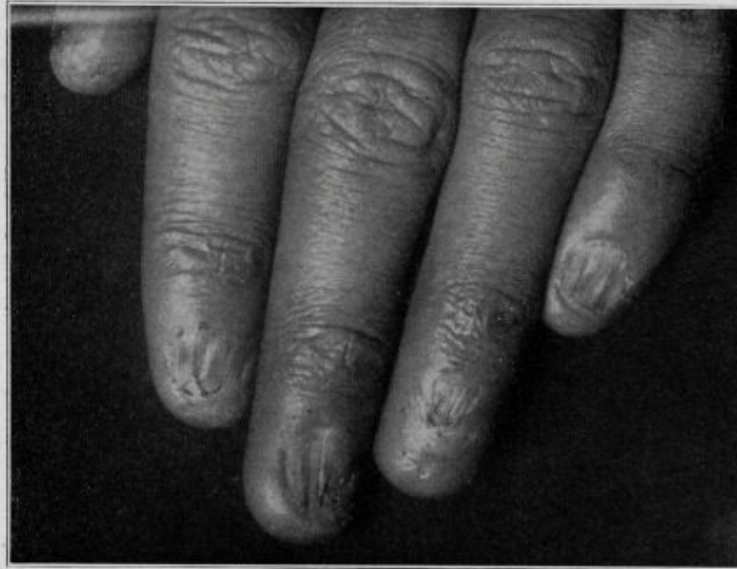

Fig. 4.—Dystrophic condition of the finger-nails. The suggestive anetoderma over the dorsum of the last phalangeal joint should be noted.

They tended to converge somewhat like a pyramid, toward the distal end, and there was no free cutting margin, but here again the substance of the nail fused into the tissue of the skin. The nails showed raised, longitudinal grooves, the interlongitudinal portions being raised and plicated somewhat. There were a certain number of longitudinal cracks of the nails as well. The nail of the third finger on each hand was atrophic in type; the one on the left was notably so, having almost entirely disappeared.

Nails of Toes: The nails of the great toes approached normal more closely than those of any other digits. They had a free cutting edge, though the one on the right foot resembled more closely the description of the nail given for the hand. The remainder of the toe-nails had an appearance much like that described

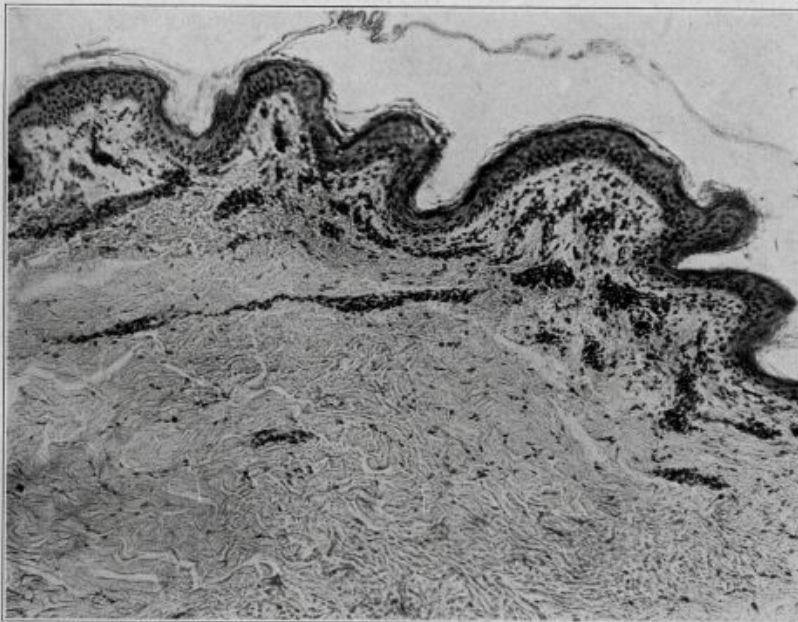


Fig. 5.—Area illustrating low epidermis, parakeratosis, dyskeratosis, dyskeratosis of prickle cells and dense clumps of pigment cells in the upper corium, along with some cellular infiltration, mononuclear in type, and some edema of the tissues. Hematoxylin and eosin stain; $\times 100$.

for the fingers, though the nail of the third digit of each foot showed the tendency to a cone formation. The nails of the little toes were atrophic.

Further examination showed no abnormalities. The hair was of normal texture. Examinations of the blood gave negative results. Roentgen examination revealed no tumors.

Histologic Study of Tissue.—Specimens of tissue were taken from different areas on the patient's body. A small section was procured from the tongue but was unsatisfactory, and the patient refused to let us take any more. One portion of tissue was removed from a section of the neck from an area in which there was not such a prominence of the tubercles; another one was taken from a region

in which the tubercles were more prominent. The stains used were hematoxylin and eosin, van Gieson's stain, acid orcein, Mallory's eosin and methylene blue (methylthionine chloride, U. S. P.) and Mallory's phosphotungstic-acid stain.

Section Showing Less Marked Changes: The epidermis was low, with little or no papillary arrangement. It was only four or five cells in thickness. There was a slight amount of parakeratosis, up to two or three cells, and scattered here and there throughout the epidermis one noted dyskeratotic changes of the prickly cells. There was some slight increase in the vessels, especially just under the epidermis. The endothelial cells were somewhat swollen and the vessels enlarged with a little mononuclear cellular infiltration around them. Scattered, especially around the vessels, but noted in many different places in the upper corium, were numerous clumps of pigment cells. They were made up of dense, deep brown,

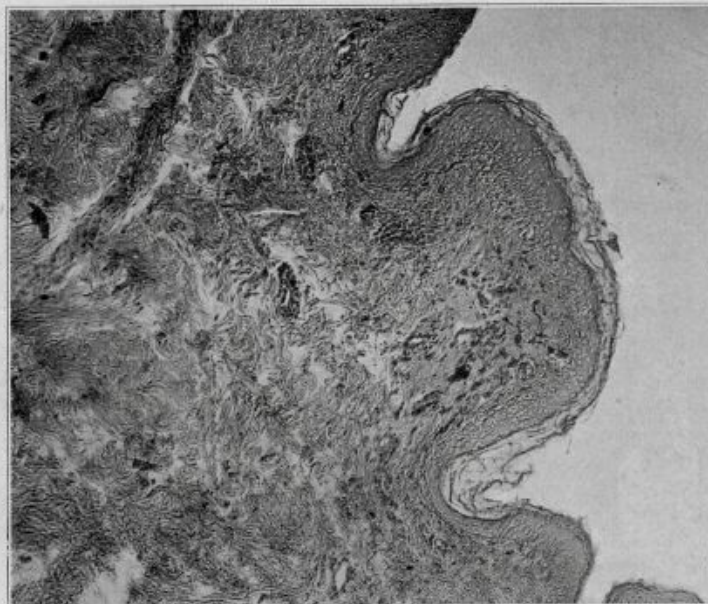


Fig. 6.—A portion of the tissue showing increased vascularity, swollen vessels, some mononuclear and cellular infiltration and edema around the vessels. Pigment cells in large clumps are to be seen. The epidermis is thin in the prickly cell layer. There is an increase in stratum corium and a dyskeratosis of the prickly cells. Hematoxylin and eosin stain; $\times 100$.

closely aggregated pigment clumps. With Mallory's eosin and methylene blue one occasionally noted strands of pigment extending from these cells even up between the prickly cells of the epidermis. The pigment was noniron-bearing, as shown by the potassium ferrocyanide test. One occasionally noted the pigment cells deep down in the corium. The collagen fibers in the upper corium seemed to be somewhat shorter, and showed some hyaline change. There seemed to be no change in the sebaceous or sweat glands.

Section Showing More Advanced Changes: The epidermal changes in this section corresponded to those in the first section. The papillae were more marked, and one noted an extensive edema of the tissues of the papillae extending far down into the corium. The vessels were swollen with their endothelial cells likewise swollen. They were increased in numbers, and there was a mononuclear cellular infiltration around them; a few plasma cells and fibroblasts were also noted. The pigment cells were observed in large clumps, not only around the vessels but even around the hair papillae. Some hyaline change was noted in the collagen fibers of the upper corium.

A month after the Cleveland meeting, at a meeting of the Chicago Dermatological Society held Nov. 25, 1926, a case was presented by

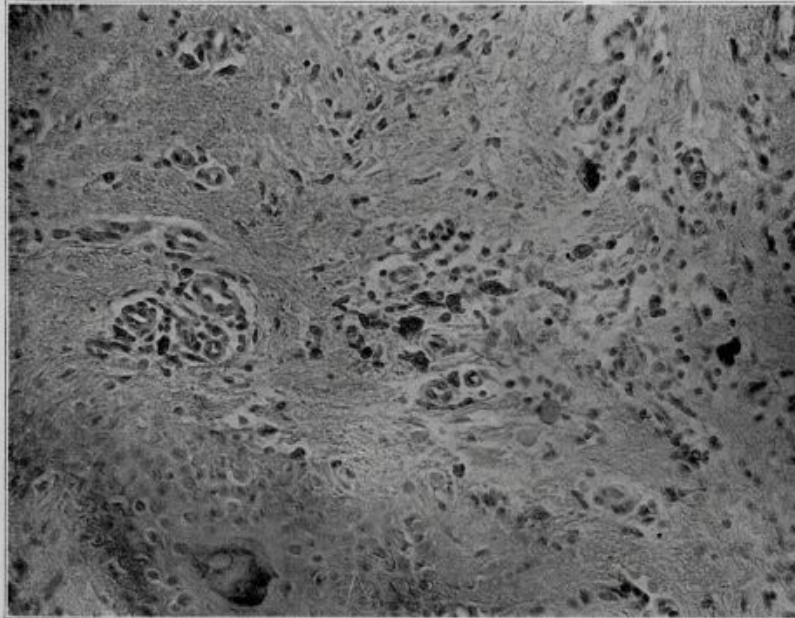


Fig. 7.—Area showing edema around the vessels which are dilated, swollen endothelial cells of the vessels and an extensive perivascular infiltration of mononuclear elements and some fibroblasts. Pigment cells are noted deep in the corium and to the right of the hair papilla. Hematoxylin and eosin stain; $\times 250$.

Dr. Martin Engman¹ under the title of "A Unique Case of Reticular Pigmentation of the Skin with Atrophy." A description of the case follows:

History.—J. L., a man, aged 22, had been under observation for thirteen years. Since the age of 9 years he had had a peculiar condition of the mouth with an

1. Engman, Martin: A Unique Case of Reticular Pigmentation of the Skin with Atrophy, *Arch. Dermat. & Syph.* **13**:685 (May) 1926.

ulcer on the left side of the tongue and a spot of leukoplakia on the right side. No disturbances of the cutaneous surfaces were noted at that time. A brother, four years younger, had spots of leukoplakia on each side of the tongue. Bacteriologic examinations gave no information of any value. The patient was not seen again until November, 1925, when he had an ulcer of the leg.

Examination.—At that time he had a peculiar condition of the skin, unusual in the color of the pigment and its distribution. The color was of a gun-metal tint, bluish to purplish gray, and generally distributed over the body. Closely examined with a magnifying glass, it was seen that the pigment consisted of a peculiar reticular arrangement. There was a small white spot, 1 mm. in diameter, surrounded by pigment. The whitish spot did not always seem to be follicular. It was deepest on the abdomen and ran markedly in a reticular distribution. It was absolutely symmetrical in its placement, similar to a nevus. Scattered irregularly over the body, especially about the neck and face, there were large, oval, unpigmented, atrophic areas, from 0.5 to 3 cm. long and 1 cm. wide. The patient said that they were sites of former abrasions or infections. On the legs were large atrophic areas which were the site of abrasions. The condition of the hands resembled an acrodermatitis chronica atrophicans. The skin was atrophic, and the nails had disappeared. The same condition was observed on the feet. The skin of the scrotum and genitalia was mildly inflammatory, crusted, and presented atrophic areas. The patient had no eyelashes. The lids were somewhat everted and inflamed. There was some atrophy of the skin of the face, and it had the appearance of being affected by a mild form of a xeroderma pigmentosum, without freckles, black spots or keratoses. The mucous membranes of the tongue and cheeks presented whitened areas of leukoplakia. The patient was normal to every diagnostic test. There were no tumors as far as x-rays could show. The patient's brother was similarly affected. His condition was not so advanced. Histologically, the epidermis was thin and edematous from excessive serum. The rete pegs were flattened, and in places the epidermis consisted of only a few cells. The dermis was likewise edematous. Lymph spaces were wide open; the elastic tissue was normal. The collagen took the stain abnormally, and the upper part was granular. All the derma down to the level of the sweat ducts was full of pigment cells containing a brown, granular pigment which was iron-free. The sweat glands and ducts were normal.

In discussion, Dr. Francis Senear, Dr. James H. Mitchell and Dr. Edward Oliver of Chicago, all experienced dermatologists, observed that they had seen our case the month before and that it was an identical type of pigmentation. Dr. Senear made the observation that the dystrophy of the nails in our case was not exactly like this. Dr. William Allen Pusey, in discussion, said that he had seen a patient with a similar condition during the last few years, who had a pigmented area around the neck with punctate white mottling, which he took to be a congenital peculiarity. He thought the fact that the patient in Engman's case had a brother with a similar condition was highly suggestive of a congenital defect.

Though we have not seen Engman's cases, we are inclined, from careful study of the short report thus far available, to think that they

are similar to our case. The picture of atrophy is more pronounced in Engman's cases, but the changes in the nail correspond exactly. The peculiar whitish papule of the skin with the grayish-red zone around it—with, in our case, the reddish zone—likewise roughly corresponds. Both patients have a condition of the hands which resembles acrodermatitis chronica atrophicans. Moreover, both patients have symptoms of leukoplakia in their mouths. Engman's cases were familial and probably congenital. The condition in our case had been present as long as the patient and his family could remember. Again, the histologic picture seems to be similar in both cases—low epidermis, dyskeratotic prickle cells, numerous iron-free pigment cells in the upper corium, and extending deep down to the hair follicles and sweat glands; edema and cellular infiltration around the vessels of the upper corium; and swollen, shortened collagen fibers in the upper corium showing hyaline changes. We are therefore taking the liberty of studying Engman's case in connection with our own.

The history of age, the long duration, the dystrophy of the nails, the acrodermatitis chronica atrophicans appearance of the fingers, the pigmentation and the keratoses and leukoplakia of the mucous membrane of the mouth all suggest to us one of the congenital anomalies or dyscrasias. Probably the cases should be looked on as belonging in the group of the dyskeratoses.

In attempting to find similar examples of this unusual chain of effects, we have been more or less unsuccessful. Certain descriptions will, in some ways, correspond to ours and in others will differ materially. For example, some of the cardinal symptoms in our case have been reported in cases of Darier's disease, in erythrodermie ichthyosiforme congénitale, in epidermolysis bullosa dystrophica and in pachyonychia congenita of Jadassohn and Lewandowsky. On the other hand, there are some symptoms in our case which are foreign and not to be found in the diseases mentioned or in allied dyskeratoses. This naturally forces us to review and to discuss some of these conditions at some length. Possibly thereby we shall be better able to distinguish sharply defined groups of symptoms characteristic of this or that condition and also to determine whether they are in any way related to the condition in our case. We believe with Rothe² that as far as possible dermatologists should attempt to separate cutaneous effects into distinct groups rather than to jumble them indistinguishably together. We can all remember the time when "typhoid pneumonia" was a common diagnosis, and in our specialty it was not so long ago that the term eczema covered a multitude of evils.

2. Rothe, L: Arch. f. Dermat. u. Syph. **102**:229, 1910.

In the hope of achieving this differentiation, or at least of making it easier to separate the dyskeratoses, Lenglet,³ in 1903, in Brocq's clinic, enumerated the following main symptoms:

1. Agénésie or dysgénésie of the hair and nails (that is, the absence of effective function).
2. Functional disturbances of the sweat and oil glands.
3. Keratoderma palmaris et plantaris.
4. Exfoliation generalista (exfoliation, lamellar in type, of the new-born).
5. Hyperkeratosis typus: ichthyosis foetalis.
6. Hyperkeratosis typus: ichthyosis vulgaris.
7. Congenital ichthyosiform erythrodermia (Brocq).
8. Skin atrophies and deep atrophies.
9. Acanthokeratolysis congenital, bullae formation.
10. Epidermolysis bullosa—simple form.

To the "termes principaux" of Lenglet, Jadassohn⁴ has since added three cardinal symptoms: pigmentations, anomalies of the mucous membrane of the mouth and anomalies of the teeth. He agreed with the Lenglet dictum that bullae are one of the best manifestations of congenital dermatoses.

It might be well to add another symptom not connected with the skin, but often seen in patients suffering from this type of dyskeratotic lesion, we refer to physical defects and to maldevelopments of the central nervous system (Klein⁵ and Henriks⁶). Moreover, there should probably be added a fifteenth symptom, as mentioned in the cases of Brünauer,⁷ Burns,⁸ Schäfer,⁹ Thibierge,¹⁰ Kreibich¹¹ and Hübner¹² and others—punctate to diffuse lesions over the corneas.

As can be seen from glancing over these fifteen principles in connection with the dyskeratoses, our case and the two cases of Engman have many of the symptoms in common. Many of these symptoms, however, are seen in greater or lesser degree with several of the other dyskeratotic diseases, and we believe it might be well to consider more fully some of them in differential diagnosis from our case.

Ichthyosis vulgaris is of itself and in its ordinary form a simple enough dermatologic condition. It has long been looked on as a familial

3. Lenglet, E.: *Ann. de dermat. et syph.* **4**:369, 1903.

4. Jadassohn, J.: *Verhandl. d. deutsch. dermat. Gesellsch.*, IX Congress, Bern, 1906, p. 381.

5. Klein, Alfred: *Arch. f. Dermat. u. Syph.* **124**:571, 1917.

6. Henriks, J., and Henriksen, P.: *Norsk. Mag. f. Laegevidensk.* **84**:1, 1923; *abstr.*, *Zentralbl. f. Haut- u. Geschlechtskr.* **9**:106, 1924.

7. Brünauer, S. R.: *Dermat. Ztschr.* **42**:6, 1924.

8. Burns, Frederick S.: *J. Cutan. Dis.* **33**:255, 1915.

9. Schäfer, Erich: *Arch. f. Dermat. u. Syph.* **148**:425, 1925.

10. Thibierge, G.: *Ann. de dermat. et syph.* **3**:717, 1892.

11. Kreibich, C.: *Deutsche med. Wehnschr.* **34**:917, 1908.

12. Hübner, W.: *Monatsh. f. prakt. Dermat.* **24**:38, 1897.

disease. Henrichs⁶ has called our attention to a series of ichthyotic families with mental disease. There were several generations in which the diseases appeared alternately or simultaneously. He stated the belief that they are due to primary ectodermal anomalies. Ideas in regard to its causation are various and need not be discussed here. However, as Bettmann¹³ in his masterly monograph on "The Malformation of the Skin" well brings out: "If, in diagnosis, in addition to an ichthyosis vera, we consider clinically and histologically the border line and mixed cases in relation to anomalies of cornification and to certain nevi—under those conditions we sometimes have difficulties in differentiation." Bettmann (p. 724) says that "no case exists in which a hereditary keratoma of the palms and soles was present in a family of true ichthyosis or in connection with a true ichthyosis." Wolff¹⁴ stated the belief that they are related. Oppenheim,¹⁵ in discussion of a case of keratoma hereditarium palmaris et plantaris with symptoms resembling both an ichthyosis and the former disease, and in which two sisters had like symptoms, said that he felt that the differences between the two diseases were not sharp. He said that he saw few cases of keratoma palmaris et plantaris which did not show the effect of ichthyosis on the extensor surfaces. Kren thought the case shown was a pure ichthyosis and Riehl, an ichthyosis with atypical localization on the ulnar side of the palms.

Vörner,¹⁶ in Riehl's clinic, thought that the two diseases should be sharply differentiated, likewise cornu cutaneum and ichthyosiform nevi. Waelsch¹⁷ felt that the term nevus unius lateralis is not always appropriate, as it may involve more than the unilateral position, hence the term nevus systematisatus, i.e., involving a certain system. Some of these nevi have certain relations to ichthyosis in which we may meet all the transitions from a simple hyperkeratosis to an extensive papillary hypertrophy. He thought that we can bring out this peculiar relationship by the additional word "ichthyosiformis." Is not this an unfortunate term, however? Would not papillomatosis be preferable for, after all, it is not ichthyosis? There are cases called ichthyosis, however, which show many of the principles of Lenglet, for example, the case of Thibierge.¹⁰ The patient was a boy, aged 12, who had had the eruption since the age of 13 days. All the cutaneous surfaces were the site of ichthyosis. There was an ichthyosis hystrix of the dorsal surface of the feet, hands and flexor surfaces of the body. The patient had the seborrheic type of

13. Bettmann, in Schwalbe, Ernst: Die Morphologie des Missbildungen, Die Missbildungen der Haut, Jena, Gustave Fischer, 1912.

14. Wolff: Arch. f. Dermat. u. Syph. **115**:1023, 1913.

15. Oppenheim: Arch. f. Dermat. u. Syph. **137**:63, 1921.

16. Vörner, Hans: Arch. f. Dermat. u. Syph. **56**:1, 1901.

17. Waelsch, Ludwig: Arch. f. Dermat. u. Syph. **114**:237, 1913.

head with alopecia of the head, ciliary and eyebrow areas. There was a thickening and folding of the mucous membrane of the buccal and nasal surfaces. Superficial opacities were noted on both corneas with radiating vessels. The palms and the soles were dry and showed numerous scattered cribriform depressions. The patient had a scrotal tongue and an opaline tint to the inside of the cheeks. The genital organs were infantile, the child was undeveloped and idiotic. Besnier called it an "ichthyosis paratypique." The case of Giovannini¹⁸ is somewhat similar. A girl, aged 13, had had an eruption since birth. There was an enormous thickening of the palms and soles with cracks—ichthyosis hystrix—and folds with an ichthyosis serpentina of the rest of the body. On the upper part of the breast, around the neck and on the head, there was a peculiar appearance resembling gooseflesh arranged regularly in yellowish, slight excrescences, which Giovannini spoke of as ichthyosis anserina. It reminds us somewhat of the appearance of our patient's neck. They did not seem, necessarily, to have any connection with the hair follicles, but rather were hypertrophied sweat ducts. The nails were thick, up to 14 mm. in thickness, and were narrower and shorter than normal. They were not always parallel with the digits and had furrows over their surfaces in different directions. Their tops were rough and broken. There was a marked alopecia. There was a thickening of the epidermis over the palms and soles and enormous widening of the sweat ducts. Both cases should probably better be called examples of Brocq's erythrodermie ichthyosiforme congenitale instead of ichthyosis.

The erythrodermie congenitale ichthyosiforme of Brocq¹⁹ has been carefully described in this country by MacKee and Rosen,²⁰ by Goeckermann²¹ and by Wile.²² The main symptoms are a redness of the skin, a marked hyperkeratosis resembling a high grade ichthyosis, a rich sebaceous secretion on the hair and face and a marked overgrowth of the hair and nails. One also notes hyperidrosis of the palms and soles and at times an alopecia, localized atrophies and changes of the mucous membrane of the mouth. Bullous lesions are a common concomitant but are not absolutely essential. Burn's case,⁸ one much discussed in the literature, undoubtedly belongs here. It occurred in a boy, aged 16, with a generalized keratoderma, impaired vision from corneal opacities and deafness. There were keratoses of the palms and soles and eruptions in the folds of the joints. The mucous membranes were also involved. Over the face there was a reticulated, grayish,

18. Giovannini, S.: Arch. f. Dermat. u. Syph. **27**:3, 1894.

19. Brocq, L.: Ann. de dermat. et syph. **3**:1, 1902.

20. MacKee, G., and Rosen, I.: J. Cutan. Dis. **35**:235, 343, 511, 1917.

21. Goeckermann, W. H.: Bullous Ichthyosiform Erythroderma, Arch. Dermat. & Syph. **14**:158 (Aug.) 1926.

22. Wile, U. J.: Familial Study of Three Unusual Cases of Congenital Ichthyosiform Erythroderma, Arch. Dermat. & Syph. **10**:487 (Oct.) 1924.

symmetrical process with underlying erythema. Because of the dystrophy of the nails and the alopecia, instead of an overgrowth, Burns was not sure whether he should classify it under Brocq's description. Brocq²³ later wrote, however, "The adnexa of the epidermis, hair and nails can show all varieties of the development from hypertrophy even to atrophy." Undoubtedly the cases of Thibierge and Giovannini belong under this grouping rather than under ichthyosis. Here, also, would be placed the case of Goldsmith²⁴ and the one described by DuBois.²⁵ The main effect in this case was a marked onychogryphosis, leukoplakia formation in the mouth, pigmentary lesions and a papillomatous eruption most marked on the palms and soles, and on the latter location often accompanied by bullae. A family history of the condition is not uncommon, witness the case of Bettmann¹³ and the two cases in children reported by Wile.²²

Another of the congenital dyskeratoses which should be mentioned in passing is one already spoken of in connection with both ichthyosis and erythrodermie ichthyosiforme congenitale. We refer to keratoma palmaris et plantaris hereditarium. Balzer²⁶ reminded us that it was called "ichthyose locale" by Besnier. Alibert, on the other hand, called it "ichthyosis palmaris et plantaris cornée." It is true that it was not present in Engman's cases and that there was only a suggestion of the condition on the palms in ours; however, it is encountered in greater or lesser form so often with the other congenital dyskeratoses that it must not be overlooked. Family occurrence is common in this condition. It is generally seen on the palms and soles only and is accompanied by hyperidrosis. There are a few cases with lesions also on the back of the fingers and hands. Bettmann questioned the placing of Raedeli's case in this classification, as there were areas on the knees, over the shins and on the labia majora. Riehl,²⁷ in a discussion of a case of this disease said that he had seen the lesions not only diffuse, but also linear in type.

Neither Engman's cases nor our own show sufficient symptoms in common with the disease already mentioned to give us any help as to the diagnosis. Another of the dyskeratoses, however, possibly approaches a little nearer to our case—we refer to the dystrophic form of epidermolysis bullosa. Besides the bullae formation of the ordinary epidermolysis, we find in this condition atrophy of the skin and involvement of the nails. Miliaria may be found in both the simple and the dystrophic

23. Brocq, L., and Fernet, P.: Bull. Soc. franç. de dermat. et syph. **19**:327, 1908.

24. Goldsmith, W. N.: Brit. J. Dermat. **40**:59, 1928.

25. DuBois: Ann. de dermat. et syph. **6**:602, 1925.

26. Balzer and Deshayes: Ann. de dermat. et syph. **7**:386, 1906.

27. Riehl, in discussion on Brauer, August: Arch. f. Dermat. u. Syph. **114**:211, 1913.

epidermolysis bullosum. Bettmann gave the only example in the literature of the anomaly in four generations with the dystrophic form of the upper extremities and with the simple form of the lower extremity. Heredity is less common with the dystrophic form, and it is oftener later in appearing. Moreover, in the dystrophic form, the changes are usually seen on circumscribed areas—hands, feet, elbows and knees. Siemens²⁸ and Goldsmith²⁴ thoroughly discussed the entire subject of the bullous dermatoses. Siemens, from Jadassohn's clinic, stated the feeling that the term epidermolysis is often histologically incorrect and should be dropped for the more preferred term, *bullosis mechanica*, adding the term *simplex*, *dystrophica* or *tarda* for the respective type of the disease. We are inclined to accept the suggestion.

There is still another dyskeratotic process that should probably be considered at this point because of its confusing group of interrelating symptoms. In 1892, Brooke²⁹ reported under the title of "*Keratosis Follicularis Contagiosa*" what he thought had been an epidemic, in which he saw six children in one family and later three in another family on whom an eruption appeared on the neck, later on the arms, thighs and trunk, with papular, blackish spots which projected from the skin. He said that the skin was dry and that the papules showed a subacute inflammation; later, spines which rattled like scraps of metal as they fell and which left gaping plugs, could be removed from these papules. He said that there were some of them seen on the face but that the scalp was free. He treated them all with emollients and reducing substances, and they seemed to get well.

Morrow³⁰ had already reported a case which he termed "*keratosis follicularis*" associated with fissuring of the tongue and leukoplakia buccalis. This was observed in 1886. It was seen in a man, aged 21, and was said to have been of five years' duration. There was a grayish or brownish discoloration of all parts of the body except the face, palms and soles. The skin felt like the surface of a calf's tongue. The ducts of the sebaceous glands protruded and were occupied by round or comedo-like, grayish, dark substances with a spinous prolongation of from one-fourth to one-half inch in length. When pressed out, they were hard and dry and left a sticky substance at the base. In the mouth it was noted that the soft palate and the roof were studded with innumerable white, minute, brownish spots embedded or depressed, while the tongue, which was large, thick and flabby and rough, was rather whitish, pasty and deeply fissured. The buccal mucous membrane had an opaline or a bluish-white appearance, and there were thickened and raised furry, distinct tracts which were superficially fissured.

28. Siemens, H. W.: *Arch. f. Dermat. u. Syph.* **139**:62, 1922.

29. Brooke, H. G.: *International Atlas of Rare Skin Diseases*, 1892, vol. 7, plate 22.

30. Morrow, Prince A.: *J. Cutan. and Ven. Dis.* **4**:257, 1886.

Little³¹ presented two cases with similar symptoms before the London Dermatological Society. Barbe³² reported the cases of two patients, aged 7 and 8, both of whom had congenital syphilis. The condition cleared up for a time under treatment with hydrargyrum internally administered but recurred promptly. Peyri-Rocamora³³ described an epidemic of something possibly like this condition in an asylum where fourteen children had a follicular eruption on the extensor surface, the folds of the joints and on the neck. This was made up of a hard cornification of the follicles, even hairy spines, from 0.5 to 1 or even 3 mm. high. They were a dirty white, yellowish or gray. There was some scaling. In some of the cases, there was also a *perlèche*. In some of the children, there were as many as from 50 to 200 elements. He thought that his cases were like Brooke's cases and quoted Brooke as having quoted Erasmus Wilson, who called it "*ichthyosis sébacée cornée*." Brooke quoted Hardy as having called it "*acne sebacé*." Lewandowsky³⁴ saw a man from India with an eruption of the extremities, extensor surfaces, back of the hands, gluteal regions, cheeks, ear and neck. The process was made up of numerous papular brownish lesions with a central horny mass which stuck out. He pressed this out, and it left a central depression. The skin between the lesions was normal. The corners of the mouth showed a high grade leukoplakia; otherwise there was nothing abnormal. Histologically, the process showed the "*corps ronds*" present, but he called it a keratosis follicularis Brooke-Morrow. There was no pigment, nor was syphilis present. He felt that in differential diagnosis one should consider a lichen spinulosus and Darier's disease. In the former disease there would be more group formation, while a keratosis follicularis is a diffuse process. Moreover, the latter is prominent on the extremities, while a lichen spinulosus is seen on the buttocks and on the back. Moreover, in lichen spinulosus all the lesions are of the same size, while in a keratosis follicularis they vary. He thought that it would be somewhat difficult to differentiate between this condition and Darier's disease. In Darier's disease there was more involvement of the inguinal regions, the genitalia, the abdomen, the head and the face. He did not feel that the "*corps ronds*" were specific for Darier's disease, that they could be seen under other conditions, though they were always present in Darier's disease. He said the French school called Brooke's disease "*acne cornée*." He did not feel that it was a parasitic disease, and said that we should drop the word *contagiosa* and call it keratosis follicularis Morrow-Brooke. Schäfer⁹ thought that the changes in this condition

31. Little, Graham: *Brit. J. Dermat.* **13**:417, 1901.

32. Barbe: *Ann. de dermat. et syph.* **2**:535, 1901.

33. Peyri-Rocamora, A.: *Ann. de dermat. et syph.* **3**:209, 1922.

34. Lewandowsky, F.: *Arch. f. Dermat. u. Syph.* **101**:5, 1910.

can never be called congenital and that they are easily influenced therapeutically. Whether, as Siemens mentioned, it is due to the action of poor soap, metallic dust (Blaschko), lubricating oil (Frieboes), petrolatum, paraffin or emery powder (Oppenheim³⁵), or whether there is actually an excitant the removal of which causes healing, must be determined by further researches.

When Engman's case was shown at the Chicago Dermatological Society, the question was brought up by Pusey whether the process might be related to a juvenile type of acanthosis nigricans. The same point was made by Wile, who stated that the condition was unique. Wieder³⁶ recently reviewed the cases of this disease in connection with a case report concerning a girl seen at the ages of 10 and 13 in Wile's clinic. These cases have been seen as early as early infancy, at the age of 3 years and up to the age of 14 years in Neuman's cases. The process is essentially a pigmentation with keratotic hypertrophy. Ormsby³⁷ reminded us that there may be partial alopecia and changes in the nails with the condition. Reported lesions of the mucous membrane, however, are papillary or verruciform instead of the atrophic type as in Engman's cases and in our own case. Moreover, the parts ordinarily affected in this disease were exempt in our own case. Here again, while there are some points of resemblance, we believe that on the whole the cases of Engman and our case belong in a different group. Bettmann quoted Bogrow as placing the juvenile type of acanthosis nigricans (*dystrophie pigmentaire et papillaire*) nearer to Darier's disease or to atypical ichthyosis.

That Darier's disease has points in common with many of the congenital dyskeratoses is unquestioned. Rothe,² in 1910, and Spitzer,³⁸ in 1921, both from Jadassohn's clinic, have thoroughly discussed this subject. In this condition one may find characteristic longitudinal folds extending even down into the substance of the nail. The ends may be thickened and jagged. Moreover, changes in the mucous membrane have been observed. The family occurrence of the condition is too well known to mention. Pigmentations of the skin are present. Moreover, as in other congenital dyskeratoses, mental disturbances and anomalies are sometimes seen. Naturally, in this condition one has histologic changes that are so characteristic that in a given questionable case this in itself should be sufficient, if absent, to rule out Darier's disease. The follicular papular and later perifollicular papular eruption observed by

35. Oppenheim: *Wien. klin. Wchnschr.* **21**:260, 1921.

36. Wieder, L. M.: *Acanthosis Nigricans*, *J. A. M. A.* **87**:1964 (Dec. 11) 1926.

p. 495.

37. Ormsby, Oliver: *Disease of the Skin*, Philadelphia, Lea & Febiger, 1927,

38. Spitzer, Rudolf: *Arch. f. Dermat. u. Syph.* **135**:362, 1921.

Nicolau³⁹ in forty-four scorbutic soldiers would not be of a type to be considered in this paper. The process had no family relationship; it was seen in undernourished soldiers with scurvy and appeared as a papulokeratotic and even ulcerative eruption of the upper part of the extremities, abdomen, lower part of the heels and side of the torso. In some cases, the eruption was the premonitory symptom.

In 1905, Jadassohn and Lewandowsky⁴⁰ saw a girl, aged 15, with peculiar congenital changes in the nails. The nails were greatly thickened, were hard and had to be cut with a chisel. The finger-nails were long and narrow, smooth and shiny, rather transparent and, toward the tips, grayish. They were thick at their free ends and curved over transversely, like a sickle. The toe-nails were likewise thickened, especially that of the great toe, resembling an onychogryphosis. Growth was not especially rapid. There were no subjective symptoms in connection with the nails. The hair of the head showed no abnormalities. On the face, especially around the nose and the fold of the chin were red, pointed papules. On the nose there were vesicles with an alkaline reaction. There was hyperhidrosis of the nose, hands and soles of the feet. Generally in summer, rarely in winter, large bullae would form on callosities of the feet; there, too, the fluid from the vesicles was alkaline. Over the elbows and knees there were several grouped, slightly indurated, reddish papules the size of millet seeds. In their centers there was a not prominent hairy plug. The dorsum of the tongue was covered with an adherent, here and there, sharp and unequally bounded, whitish plaque. There were whitish strands on the borders of the tongue, some slightly raised. From time to time the patient showed an eruption on the scapulae and in the axillary spaces and gluteal region. There were irregular disseminated lesions, like the ones on the elbows and knees. The patient had a brother, aged 4, with a similar eruption.

Histologic study of a lesion with a horny cone showed a hyperkeratosis of the follicle and parakeratosis. The rete was thick and protruded deep into the cutis. The rete cells were vacuolated. In the cutis, there was a light edema and a little increase in cells. In a discussion of their case, the authors mentioned Darier's disease and keratosis follicularis Brooke. They did not feel that the symptomatology in either condition fitted that of their patients, and because of the prominent symptoms of the nail they suggested the term pachyonychia congenita. Their cases were presented by Lewandowsky⁴¹ before the ninth Congress of the German Dermatological Association in 1907. As long ago as 1904

39. Nicolau, S.: *Ann. de dermat. et syph.* **7**:399, 1919.

40. Jadassohn, J., and Lewandowsky, F.: *Ikonographia dermatologica* **1**:29, 1910.

41. Lewandowsky, F.: *Transactions of the Eleventh Congress of the German Dermatological Association, Berlin, Julius Springer, 1907, p. 333.*

Wende⁴² had reported the case of a child, aged 5, with symptoms somewhat resembling those already described. The condition began apparently when the patient was about 2 years of age. The child was bald from birth and showed comedo-like lesions over the head. There were bullae of the feet and later of the fingers, while the nails were thin and brittle and longitudinally striated. Both the hands and the feet showed a hyperhidrosis, while the finger-tips were atrophic, though x-ray pictures revealed no abnormalities. Naturally the query may be raised as to whether the condition was an epidermolysis bullosa dystrophica or bullosa mechanica dystrophica of Siemens; nevertheless, many of the symptoms coincide with those in the foregoing cases. Gaucher and Milian,⁴³ in 1905, reported a case with extensive keratosis palmaris et plantaris, agnesia of the hair, sudoriferous cysts with sebaceous contents, langue scrotale and leukoplakia of the mucous membrane of the mouth. The patient had a dry skin and pigmentation with keratotic lesions. At the tenth congress of the German Dermatological Association in 1908, Bettmann⁴⁴ showed a boy, aged 8, with lesions almost exactly like those in the patients of Jadassohn and Lewandowsky. He had identical changes in the nails, and there was a tendency to bulla formation on different parts of the body. The relation to epidermolysis bullosa seemed close; however, there was a leukokeratosis of the tongue and disseminated follicular keratoses of varying intensity. The patient also had a hyperhidrosis of the palms and soles and a granulosus rubra nasi. He had four brothers who were exempt from the disease. Bettmann (p. 735), in 1912, reported that he also had had as patients a father and three sons, the youngest 8 years of age, with similar congenital dystrophies of the nails, extensive leukoplakia of the mucous membrane and disseminated follicular keratoses of the skin. He also quoted Hartzell's case with leukoplakia and follicular keratoses and Babicek's with pachyonychia, symmetrical keratoses of the palms and soles, follicular keratoses and hyperkeratoses and deformities of the knees, elbows and teeth. In Dunn's⁴⁵ case, possibly questionable here, the patient had a keratosis palmaris et plantaris with alopecia totalis except for the top of the head. At puberty the hair was thicker on the head but never on the temples. There was a hyperhidrosis of the palms and soles, while the nails were thickened and the free edges broken—as in trichophytosis. The teeth were normal, and there was no family history. In Riehl's⁴⁶ patient, aged 23, there were callosities of the palms and soles, more

42. Wende, G. W.: *J. Cutan. Dis.* **2**:14, 1904.

43. Gaucher and Milian: *Ann. de dermat. et syph.* **6**:609, 1905.

44. Bettmann: *Transactions of the Tenth Congress of the German Dermatological Association, Berlin, Julius Springer, 1908, p. 378.*

45. Dunn, James: *J. Cutan. Dis.* **28**:191, 1910.

46. Riehl: *Zentralbl. f. Haut- u. Geschlechtskr.* **6**:335, 1923.

linear-like, and also callus-like lesions on the dorsa of the toes. There was a pachyonychia of the nails and a leukoplakia of the hard palate, cheeks and gingiva. The patient also showed keratosis pilaris of the calves; the joints were hyperflexible, and the patient had nervous manifestations. In Strandberg's⁴⁷ patient, the nails were thick and of a dirty gray color with smooth surfaces. There was hyperkeratosis with vesicles on the feet and callosities. The skin otherwise was normal. In Siemen's²⁸ patient, both the boy, aged 10, and the mother suffered from an eruption of the knees, elbows, buttocks and thighs, follicular in type, with a central blackish-brown, hairy plug. There were keratoses of the palms and soles, with sweating. The nails showed a pachyonychia and terrace formation of the ends. The nail-folds were a dirty black. In the axillae there were arsenical-like lesions. The tongue showed a light red hyperkeratosis and leukoplakia; leukoplakia appeared in the corners of the mouth. In Schäfer's⁹ case, a boy, aged 12, showed light red to dirty brown skin on the knees, joints of the feet, elbows, nates and axillary folds. Situated on it were follicular keratoses with a central blackish-brown cone. On the left shoulder blade were two horny spinules 2 mm. long. The skin of the face was a bluish red, and the nose, palms and soles showed hyperhidrosis. Hyperkeratoses were present over the palms and the soles, making walking difficult. The walls were thickened and rolled in the form of an omega. They were blackish and were brittle at the ends. The tongue showed leukoplakia and in spots was bright red; a whitish plaque was also present on the inside of the cheeks. There were areas of alopecia areata, and the two middle upper incisors were dystrophic. The patient had a cataract of the right eye and incomplete descent of the left testicle. Brünauer,⁷ in 1925, reported the case of a boy, aged 9, with similar symptoms and in addition a sickle-formed type of change on the cornea of the eye with keratitis. The patient had keratoses of the palms and soles, onychogryphosis, hairy formation on the limbs resembling systematized nevi and leukokeratosis in the mouth. In our country, Andrews and Strumwasser⁴⁸ reported at the 1928 meeting of the Dermatological Section of the New York State Medical Society, the case of a boy, aged 5, of low mentality, leukoplakia of the tongue, greatly thickened nails and a follicular eruption of the ankles, buttocks, lumbar region, forearms, elbows and knees. The boy at times developed waxy bullae of the feet. These authors thought that histologic study of their case showed bodies resembling "corps ronds" of Darier in the epidermis. There was no family history in the case. They also reported a case of Dr. Howard Fox which we do not believe contained sufficient evidence to be classified here.

47. Strandberg, James: *Dermat. Ztschr.* **22**:278, 1915.

48. Andrews, George C., and Strumwasser, Samuel; personal communication.

We have reported this group at some length, because we believe it to have a sufficiently definite chain of effects to justify the designation of a distinct entity—pachyonychia congenita as given it by Jadassohn and Lewandowsky. Andrews and Strumwasser were not inclined to put it down as a clinical entity but rather as an anomaly of Darier's disease, since they found bodies suggesting "corps ronds" in the epidermis in their case. Rothe, in 1910, emphasized the point that all Darier's cases will show the "corps ronds," but that one may find dyskeratoses in the epidermis in other dyskeratotic lesions that may resemble this one very much and yet not be Darier's disease. We believe their case to be a

Cases of Pachyonychia Congenita Described in the Literature Compared with Cases Reported by Us

Cases	Author	Follicular Keratoses	Circumscribed Plantaris et Palmaris Keratoses	Pachyonychia or Dystrophias	Leukokeratosis of Mucous Membrane of the Mouth	Palmar and Plantar and Nasal Hyperkeratosis	Vesicle Formation	Hair Anomalies	Congenital Tendonecrosis	Changes in Eye	Changes in Teeth	Pigmentation	Atrophy
1-2	Jadassohn and Lewandowsky	+	+	+	+	+	+	-	+	-	-	-	-
3	Bettmann	+	+	+	+	+	+	-	+	-	-	-	-
4-8	Bettmann	+	+	+	+	+	+	-	+	-	-	-	-
9	Babicek (nach Bettmann)	+	+	+	+	+	+	-	+	-	-	-	-
10	Hartzell (nach Bettmann)	+	+	+	+	+	+	-	+	-	-	-	-
11-12	Siemens	+	+	+	+	+	+	-	+	-	-	-	-
13	Riehl	+	+	+	+	+	+	-	+	-	-	-	-
14	Strandberg	+	+	+	+	+	+	-	+	-	-	-	-
15	Schäfer	+	+	+	+	+	+	-	+	-	-	-	-
16	Gaucher and Milhan	+	+	+	+	+	+	-	+	-	-	-	-
17	Brünauer	+	+	+	+	+	+	-	+	-	-	-	-
18	Andrews and Strumwasser	+	+	+	+	+	+	-	+	-	-	-	-
19	Dunn	+	+	+	+	+	+	-	+	-	-	-	-
20-21	Engman	+	-	+	+	+	-	+	+	-	-	-	-
22	Cole	+	?	+	+	+	-	+	+	-	-	-	-

true case of pachyonychia congenita. Schäfer, in a discussion of his case and in an attempt to place it, likewise felt that it was not a disease *sui generis*, but rather a systemic disease in the sense of a congenital dyscrasia. After all, however, as we look over this group of cases, we are impressed with the concordance of the symptoms. The condition is rare, and from 1905 to 1929, only eighteen true cases and one questionable one have been culled from the literature. After all, what is the study of medicine but an attempt to collect and separate groups of symptoms which seem to be most in accordance, and to attempt to set them up as distinct entities? It is only in that way that the fathers of medicine have been able to put its study and systematization on a scientific basis. We can remember the time when out of this same group of congenital dyskeratoses erythrodermie ichthyosiforme congenitale of Brocq was hardly accepted. We believe that pachyonychia congenita

is likewise entitled to a distinct niche, and as time goes on further cases will be seen, and the disease will become more firmly established.

Whether the cases of Engman and our own case should likewise be placed here or separated *de novo* is also difficult to say. Our cases present rather the picture of an atrophy of the skin. It was noted on the back of the last joint of the finger in our patient that the skin was suggestive of an anetoderma with acrocyanosis of the hands and feet. The enlarged parallel venules over the pinna of the ears were also unique. The symptoms were even more pronounced in Engman's one case of atrophic pigmentation. Moreover, this atrophic tendency was seen in the nails as well. In Engman's case they had disappeared entirely, and in ours they were stunted or dystrophic. The thickened nail is the cardinal symptom of cases of pachyonychia congenita; in fact, thereby the name is given. We remember Brocq's later statement in regard to "erythrodermie ichthyosis congenitale" that there could be all stages from a hypertrophy to a dystrophy in different types of the disease. If an attempt is not made to separate distinct groups having some symptoms in common, the question may properly be raised, why separate the dystrophic type of epidermolysis bullosa from the congenital ichthyosiform erythroderma? Or again, to go a little further, why separate Darier's disease or even keratosis follicularis Morrow-Brooke? It is only through endeavoring to classify the main groups of symptoms most closely related that we can render the study of dermatology clearer, more intelligible and more scientific. Bettmann (p. 731) has already expressly referred to the existence of such manifold combinations of congenital dyskeratoses: "they do not allow themselves to be easily arranged under the main types, but as mixed forms are especially important for the dictum that in all differentiation every type indicates a narrowly related whole. Why in a part of the cases pure single types are seen while in others very complex associations can be brought out with striking agreements is difficult to explain."

If we were to apply this dictum in our case, possibly we might consider it as belonging to the group of pachyonychia congenita. Moreover, Bettmann reported that in the father and three sons in his group of cases of pachyonychia congenita, there was a "Verkümmerungen," a stunting or dystrophy of the nails. Nevertheless for the present we are inclined to separate our case and the cases of Engman, though we have not seen them, into a distinct group of the dyskeratoses. Perhaps thereby others may pick out similar cases, or again some one later may feel that these cases should be better combined with the pachyonychia group in some other group. Purely as a provisional matter we would term them "dyskeratosis congenita with pigmentation, dystrophia unguis et leukokeratosis oris," more or less describing the main characteristics seen in the cases. That they are congenital we believe to be undoubted—witness

the histories. In one of Engman's cases, the condition was present at least from the age of 9, and as early as the patient could remember in our case. It is also familial, at least it was so in Engman's case. If Bettmann's four cases were to be placed here, this would be more evident. The main symptoms are those of dystrophy or atrophy of the nails, a peculiar pigmentary eruption of the neck and upper part of the chest in one case, and almost universal in Engman's cases, a dyskeratotic eruption of the elbows and knees, an acrocyanosis of the extremities and ears and a leukoplakia of the mucous membranes of the mouth. "The hands looked like acrodermatitis chronica atrophicans." The process is not of a type that could be classified under the ichthyoses or the keratosis palmaris et plantaris or epidermolysis bullosa (bullosis mechanica simplex, dystrophica, or tarda). It would hardly fit in the Darier's complex or with the keratosis follicularis—Morrow-Brooke. The symptoms might possibly be nearer to the juvenile type of acanthosis nigricans, but unfortunately the areas usually involved in that disease were free from lesions in our cases, and the papillomatous character of the disease was entirely absent. We believe the effect corresponds closest to pachyonychia congenita of Jadassohn and Lewandowsky, eighteen definite cases of which have thus far been described. Because of the atrophic or dystrophic type of our cases, we would separate them as still another related group and possibly as a distinct entity.

What the cause of these allied congenital dyskeratoses may be is a great question. They are often familial. Henrichs would say that the cause was a pathologic disposition of the ectoderm. Consanguinity undoubtedly plays a rôle in certain of these cases, as has been brought out in a family whose cases have been reported from Jadassohn's clinic. Siemens stated that ichthyosis vulgaris is a dominant, and ichthyosiforme congenitale erythrodermie a recessive, characteristic. Bettmann (p. 715) says that the manner of separation of the epitrichium may be of importance in all anomalies of keratinization. Lenglet expressed the same feeling. Meirowsky, according to Fischer, thinks keratoma palmaris et plantaris is a dominant characteristic. He thinks that the anomaly of the hair, nails, palms of the hands and soles of the feet is a disease of the skin in which single phenomena are coordinated and are to be conceived as a destruction of the germ plasm and inherited as a dominant character of the general germ plasm, the ectoderm.

CONCLUSIONS

1. A report is made of a case, and what seem to be two similar ones from another clinic, of a unique dyskeratosis of the skin.
2. The condition is characterized by being probably congenital and familial and is accompanied by symptoms of atrophy, pigmentation, dys-

trophic changes in the nail and by leukokeratosis of the mucous membrane of the mouth.

3. The process has some characteristics in common with the dystrophic type of epidermolysis bullosa (bullosis mechanica dystrophica), with Darier's disease and with the juvenile type of acanthosis nigricans. It probably approaches closest, however, to the syndrome described by Jadassohn and Lewandowsky under the term pachyonychia congenita.

4. We believe the characteristics of the latter syndrome to have been well enough defined and described in eighteen cases and one questionable case, which we have culled from the literature, to entitle it to the designation of a distinct disease.

5. In the three cases mentioned, the condition appears to be most like pachyonychia congenita, but because of the dystrophic effect we would provisionally suggest the name of dyskeratosis congenita with pigmentation, dystrophia unguis and leukokeratosis oris.

In conclusion we wish to express our thanks to Dr. Maurice L. Richardson and to Dr. Otto Saphir of the Pathology Department of the Cleveland City Hospital for their help in the preparation of pathologic specimens and in the making of photomicrographs.

ABSTRACT OF DISCUSSION

DR. MOOK, St. Louis: I think unquestionably the cases shown by Dr. Engman and Dr. Cole belong to the same group. In our case the boy was 12 years of age when we first saw him. At that time he had ulcers only on both sides of the tongue. The skin, hair and nails were normal. An attempt was made to diagnose the condition tuberculosis, but he had no visceral lesions of tuberculosis. We next saw him ten years later, and he had then developed the universal condition of the skin. His hair was thin, the eyelashes and eyebrows had disappeared, the nails were completely destroyed and he had pigmentation of the mucous membrane with considerable atrophy of the mucous surfaces of the cheeks. At the same time a younger brother was developing a similar condition on the tongue, and we believe that in time he will develop the same condition. In this family, at any rate, the condition is familial and probably congenital.

There was one feature about our case that was suggestive that it might belong to the nevus group, in that on the abdomen there were scroll-like lesions similar to those in nevus unius lateralis, without the keratosis. In addition, there was a line running down from the sternum to the pubis and a cross line at about the tenth ribs, so that his trunk was divided into quadrants, the upper left and the lower right being much more pigmented than the upper right and the lower left. The general health of the patient was unaffected, but the process is progressive.

DR. HOWARD FOX, New York: I was much interested to hear of this case of Dr. Cole's. It did not seem to be precisely like the one reported in the *Ikonographia* by Jadassohn and Lewandowsky as pachyonychia congenita. As Dr. Cole mentioned a case of mine and put it in the doubtful class, it might be well to discuss it. Dr. Andrews and Dr. Strumwasser who reported a case from New York considered my case almost identical with their own. The nails were thickened rather than atrophied and were precisely like the picture published in the *Ikonographia*. The

patient was a boy, about 4 years of age, who had wartlike lesions on the extremities and buttocks and a few flaccid bullae on the feet underneath callosities. He did not have leukokeratosis of the tongue, nor did he have lesions suggesting granuloma rubra nasi, but it seemed to me that it was unquestionably a case of the anomaly described by Jadassohn and Lewandowsky.

PROF. JOSEF JADASSOHN, Breslau: Dr. Cole was kind enough to show me his interesting case when I was in Cleveland. I agree with him that it is to be classified as one of the congenital anomalies, and would like to add only a few remarks.

As Dr. Cole noted, Lenglet was the first to enumerate the different symptoms which are to be found in this group. Dr. Cole and I completed this series. I want to call attention to a further symptom, namely, hyperhidrosis of the fingertips while the palms are dry. I saw this symptom in different forms of this group, even in common ichthyosis.

The well known types of congenital diffuse anomalies of the skin are characterized by typical combinations of some of these single symptoms. If this combination is a different one, then we have the atypical cases, as, for instance, Dr. Cole's case. It seems to me important to describe these cases exactly as Dr. Cole did, because they may not be as rare as our literature seems to show, and if we have no exact description, we cannot bring together the corresponding cases. This is necessary not only from a diagnostic standpoint but also for studies about the heredity of single diseases. It seems important, especially in these atypical cases, to find out whether the same atypical combination is to be seen in different members of the same family. We must always try to examine as many relatives as possible, to establish whether or not there is consanguinity of the parents, and so forth.

I want to emphasize that there are in this whole group many abortive forms ("formes frustes"). They are well known in the common ichthyosis, but as far as I can see they are not recognized, e. g., in the cases which belong to the ichthyosis paratyptica of Besnier or the hyperepidermotrophie of Brocq. I see, not infrequently, stripes of hyperkeratosis on the flexor sides of the knees and the elbows, on the front side of the axillae and on the navel. I have seen that anomaly sometimes even in several members of the same family. It seems to be not without interest that many of the single symptoms of these congenital anomalies are only exaggerations of qualities of the skin which we generally do not call anomalies. I mention hyperhidrosis, keratosis pilaris, dry and somewhat hyperkeratotic skin, etc. In this connection I must mention the dilatation and light hyperkeratosis, and later on, atrophy of the follicles of the neck and chest, and the form of the toe nails, which resembles the pachyonychia, by their strong convex (but not hyperkeratotic) forms. Perhaps it will be possible by studying these formes frustes in families to find more material for the study of heredity in skin diseases.

Finally, I want to say that the name pachyonychia described by Lewandowsky and myself is incomplete. We wanted to publish in the *Ikönographia* the results of studies of the nail form, but it will be necessary to complete this name, and we can do this only by a short enumeration of the principal symptoms. In this manner it will be necessary both to give to the new cases the right place in the group of congenital anomalies, and to individualize it in such manner that it will not be lost in the future.

DR. WILLIAMS, New York: I am much interested in this presentation for several reasons. In the first place, I am interested in the diagram showing groups of circles and straight lines, which I suppose are intended to show some sort of relationship. It is a vivid picture, satisfying to the eye, but misleading for that reason. It seems to clarify our knowledge, but really does nothing of the kind, because there is no definition of the exact relationship which is intended.

In the second place, we have a good deal of confusion because, as Professor Jadassohn has brought out, we have the occurrence in a family of a disorder with definite but varied symptoms. All the cases have certain points of resemblance, but there are many individual differences. The only conclusion, I think, is that there is some underlying fault, some dysfunction of the elements that control development.

I wish to emphasize further what Professor Jadassohn said, that if such cases are to be studied, all members of the family must be studied, and all the symptoms recorded.

The deformity of one of the nails looked, as Dr. Cole said, exactly as if it had been caused by trichophytosis. It certainly did. I have seen many of these, in which I was unable to decide whether the deformity was due to dystrophy or to an infection caused by *Trichophyton*. I believe that in many cases dystrophy, whether produced by injury, by malnutrition or by some other causes, is responsible for the greater part of the visible deformity, and furnishes a suitable ground for the growth of various organisms, including the trichophytions.

DR. COLE, Cleveland: In reply to Dr. Williams' question, I may say that at one time we wondered about the possibility of this being a parasitic process. We thought we cultivated a thrushlike organism from the tongue, and looked for it zealously in the nails. I think it is possible for a parasitic organism to get in and yet mean nothing.

I did not emphasize, possibly, as much as I should the fact that this is undoubtedly a familial disease. In the cases reported by Bettmann the father and three sons had the condition. In the report from the Jadassohn clinic there was a marked influence of consanguinity when cousins married, the flare-up in the next generation illustrating this. In our case we found no family history in this way as far back as we could go. I have not seen the case mentioned by Dr. Fox. I saw the reprint but was not sure about putting it in this group, or whether it was a type of epidermolysis bullosa. Of course, Dr. Fox saw the patient and knows far more than I could get out of the report.

As far as the circles in one of our illustrations are concerned, any one who reads anything from Brocq's clinic knows that the clinicians there are fond of circles, and this illustration was from his clinic.